

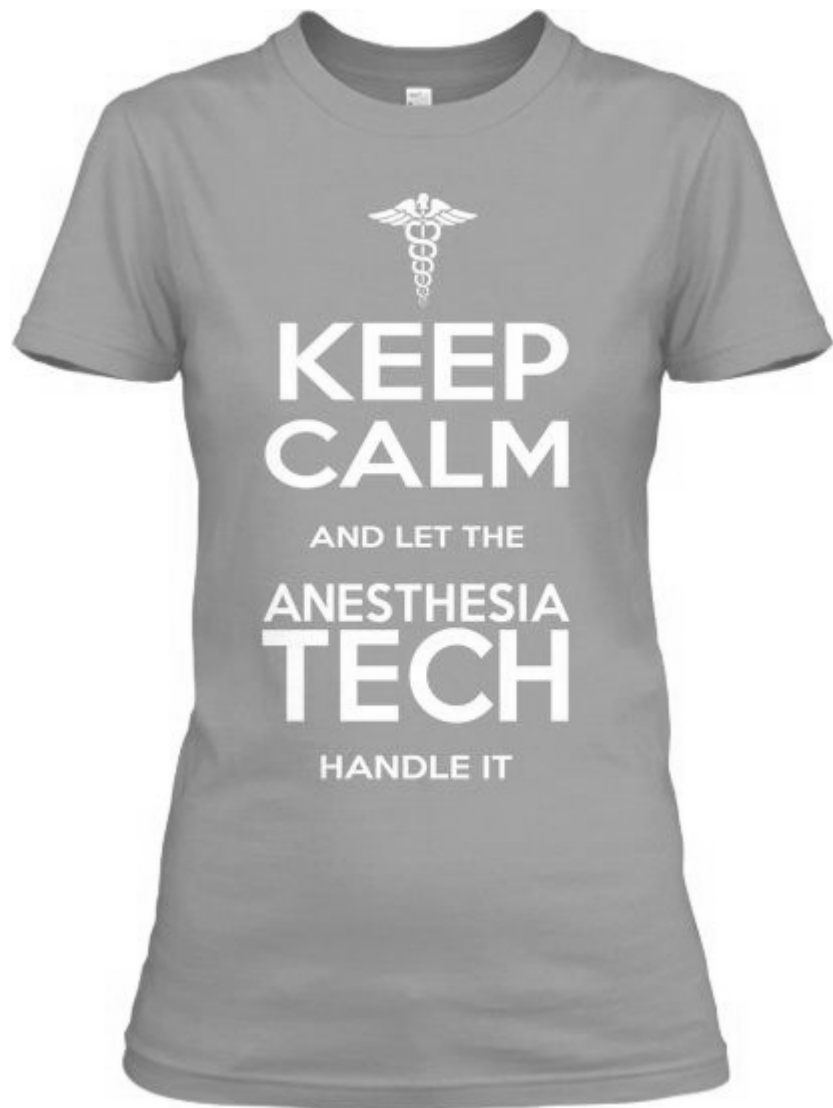# ARKANSAS 4-H VETERINARY SCIENCE



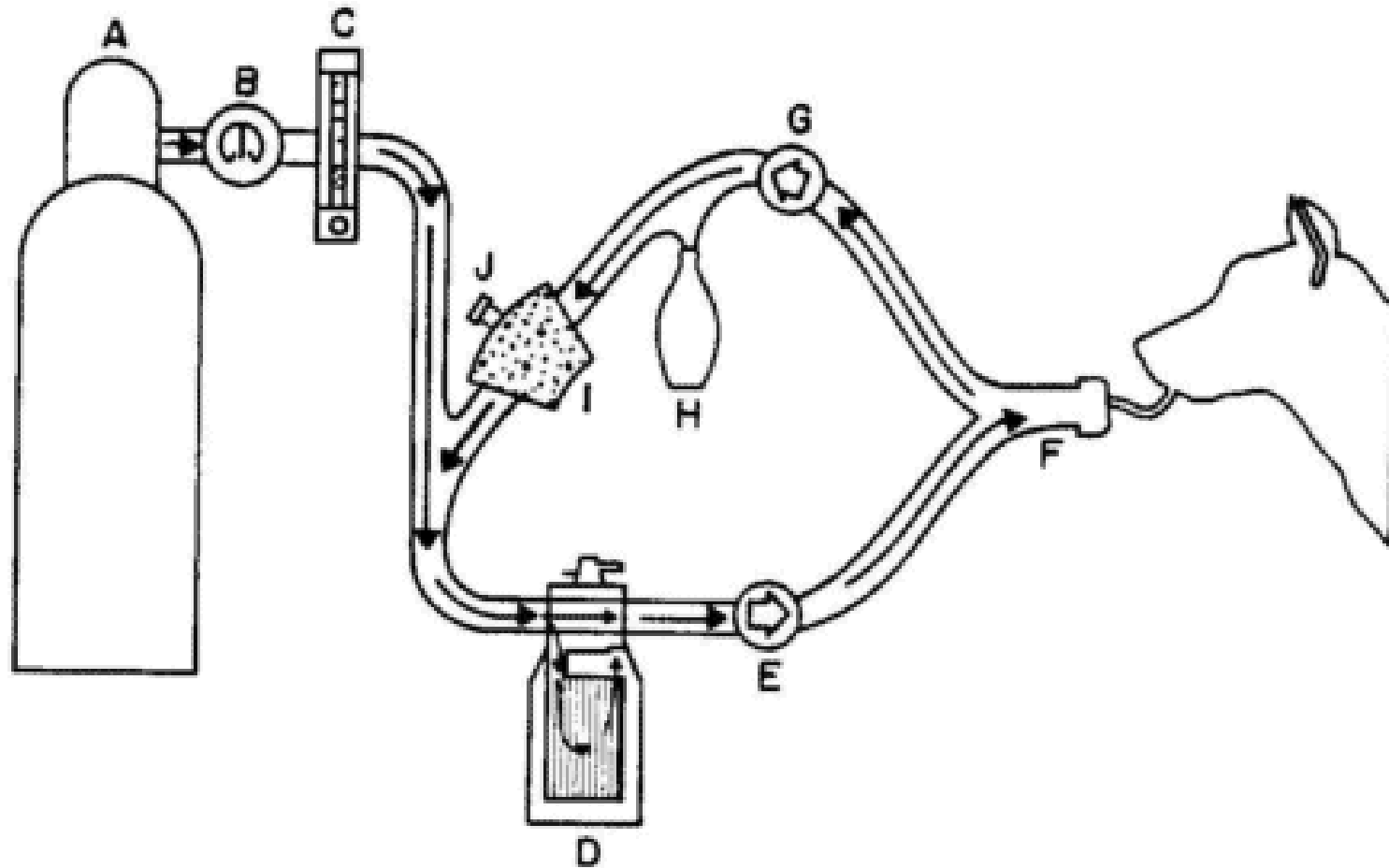
**UofA** DIVISION OF AGRICULTURE  
RESEARCH & EXTENSION  
*University of Arkansas System*



# Anesthesia



# Circle Breathing Circuit



# Circle Breathing Circuit

A.

B.

C.

D.

E.

F.

G.

H.

I.

J.

# Important Numbers

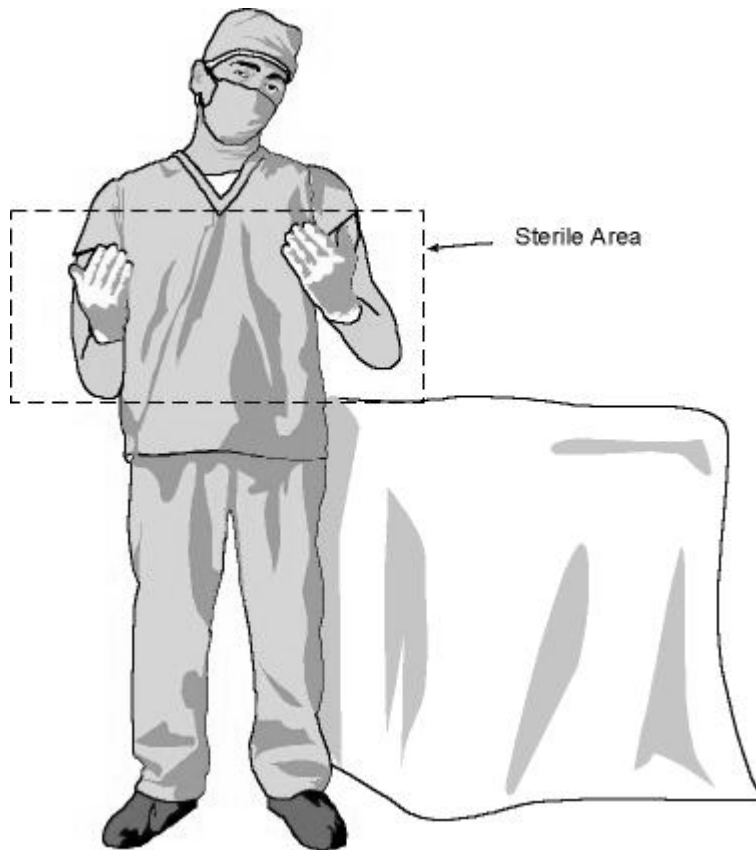
- Reservoir bag based on 10-15 ml/kg
- Oxygen flow based on 25-50 ml/kg/min
- Fluid rate 10-20 ml/kg/hr
- To get kg, divide lb by 2.2
  - A 40 pound dog weighs 18 kilograms
- Dog vital signs
  - Heart rate is 60-140 beats per minute
  - Breathing rate is 12-24 breaths per minute
  - Body temperature is 100.5-102.5°F
  - Normal mean blood pressure is 100 mm Hg
- Cat vital signs
  - Heart rate is 160-240 beats per minute
  - Breathing rate is 20-30 breaths per minute
  - Body temperature is 100.5-102.5°F
  - Normal mean blood pressure is 135 mm Hg
- Horse vital signs
  - Heart rate is 30-40 beats per minute
  - Breathing rate is 8-15 breaths per minute
  - Body temp is 99-100.5°F
  - Normal mean blood pressure is 90 mm Hg

# Sterile Technique



# What is Sterile (Aseptic) Technique?

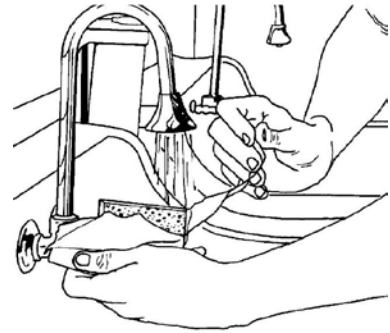
Aseptic technique is a method designed to prevent contamination from microorganisms. It involves applying the strictest rules and utilizing what is known about infection prevention to minimize the risks that the patient will experience an infection.



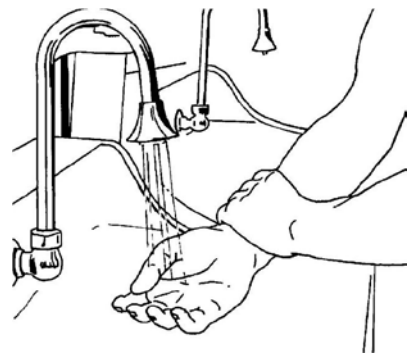


# Scrubbing in for Surgery

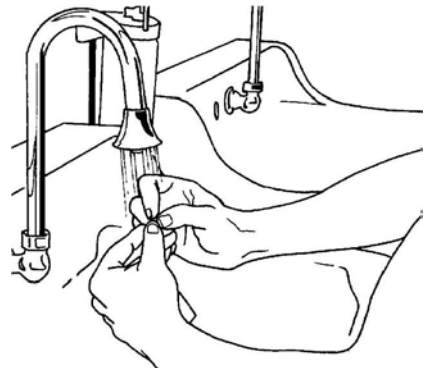
- Open sterile soap packet



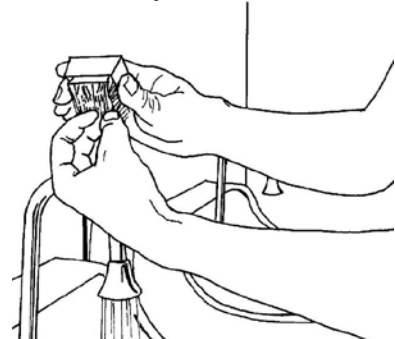
- Wet hands



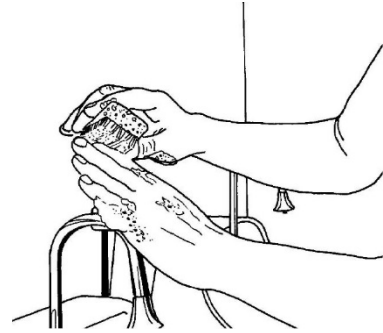
- Clean under fingernails first



- Lather and scrub fingertips  
30 circular strokes



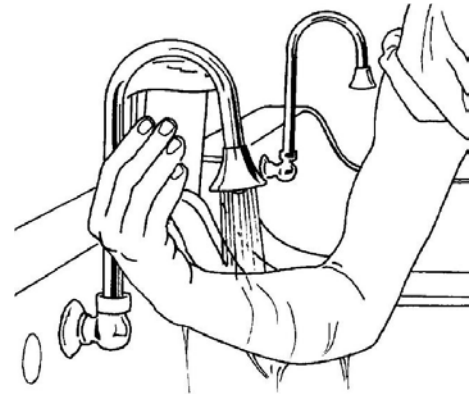- Lather and scrub digits  
20 circular strokes on all 4 sides



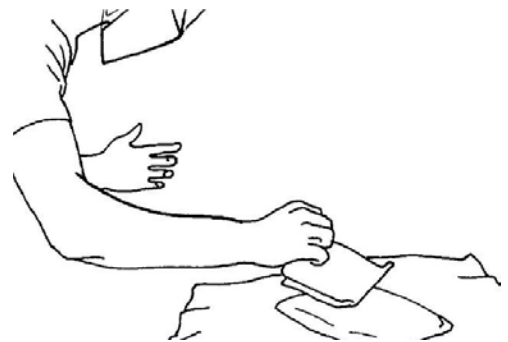
- Scrub arm up to elbow  
1 minute each side

- Repeat on other hand and arm

- Rinse starting with hands  
Allow water to flow toward elbow

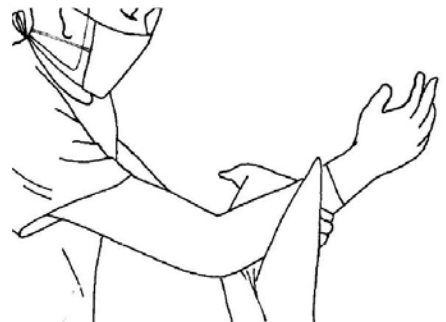

- Carefully pick up sterile towel

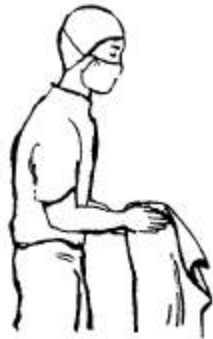

- Dry from hands to elbow

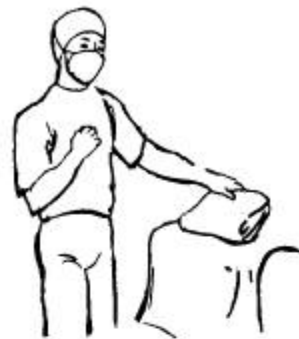Now you are ready to gown!



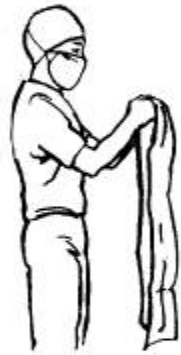# Gowning for Surgery



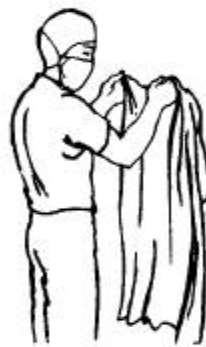1. DRY HANDS.



2. PICK UP GOWN.



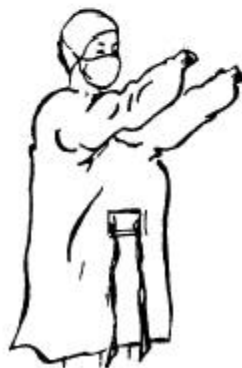3. LET GOWN UNFOLD.



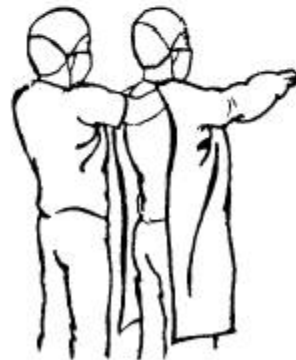4. OPEN TO LOCATE SLEEVE / ARMHOLES.



5. SLIP ARMS INTO SLEEVES.



6. HOLD ARMS OUT AND SLIGHTLY UP.




7. CIRCULATOR PULLS GOWN ON.



# Surgery Pack Wrapping

## The Spay Pack



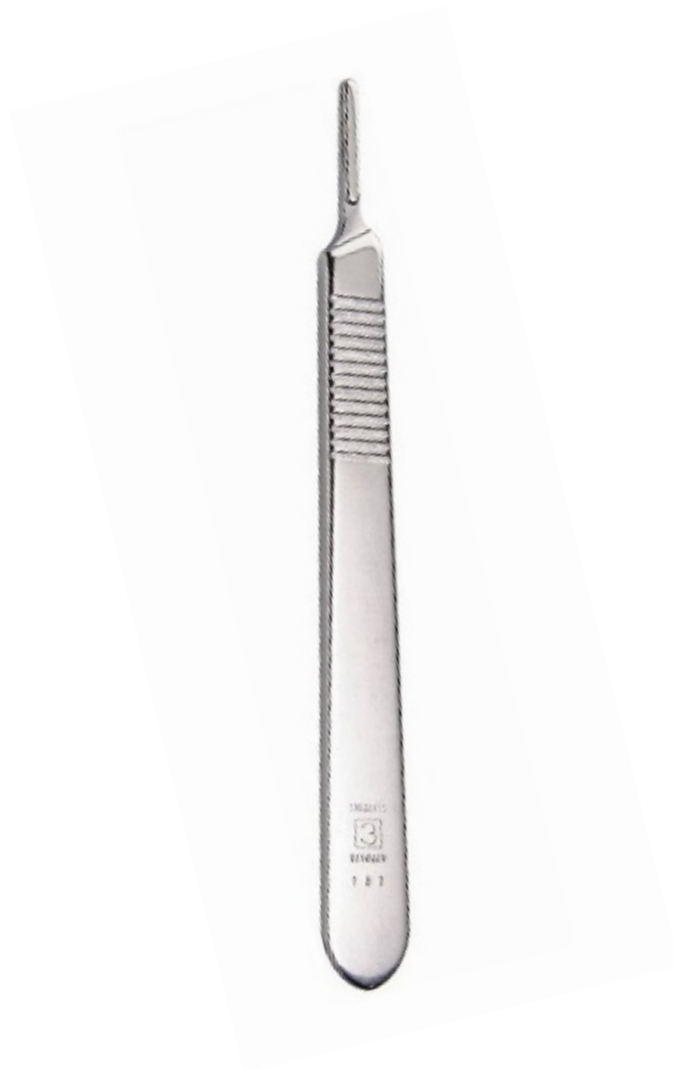# Mayo Scissors

(for cutting thick tissue)



# Scalpel Handle

(for holding scalpel blade)



# Spay Hook

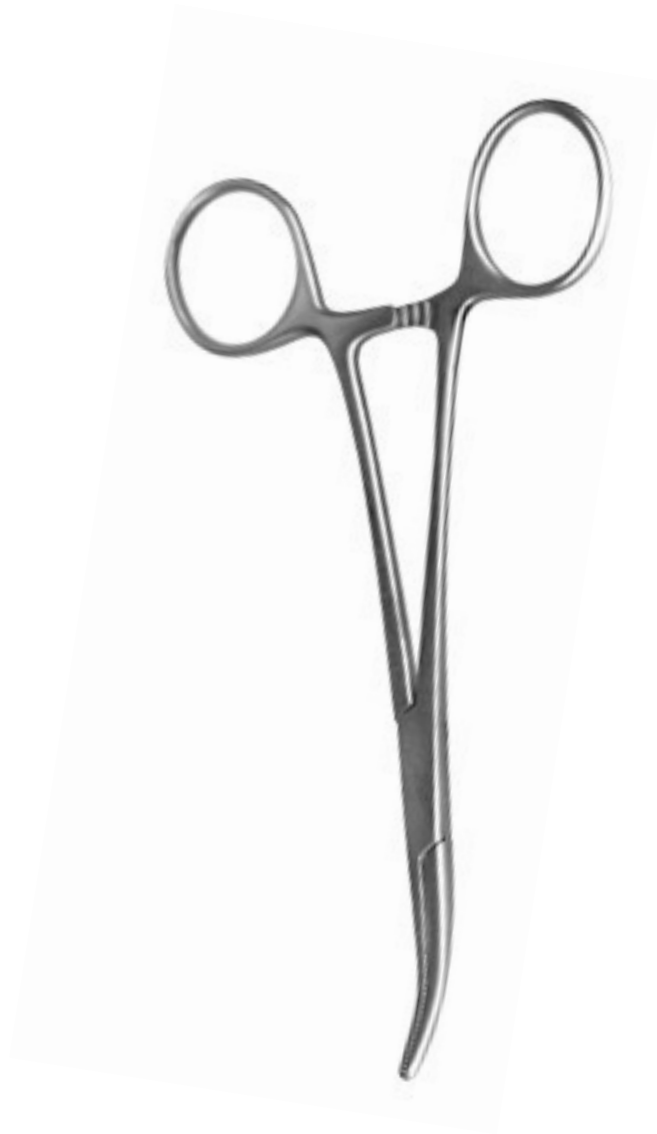(for finding uterine horns)






# Kelly Hemostat

(for clamping moderate vessels)



# Metzenbaum Scissors

(for cutting thin tissue)



# Tissue Forceps

(for grasping delicate tissue)



# Adson-Brown Forceps

(for grasping more fibrous structures)



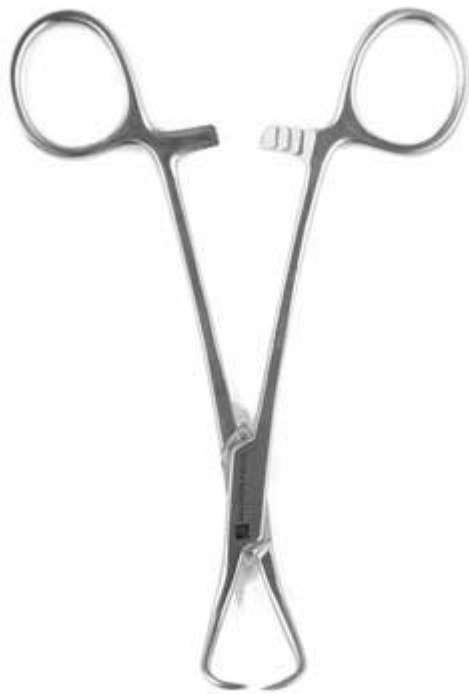# Allis Forceps

(for grasping/holding delicate tissue)




# Towel Clamp

(for clamping towel to skin)



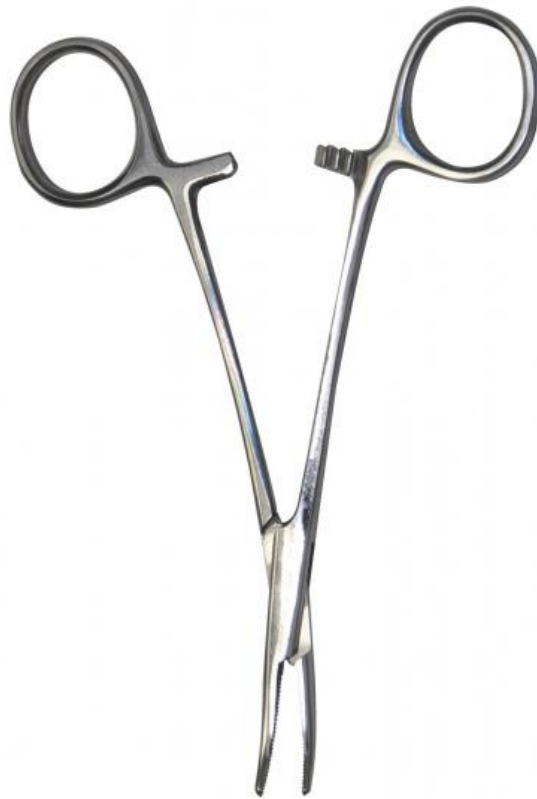# Needle Holder

(for holding suture needle)



# Mosquito Forceps

(for clamping small vessels)





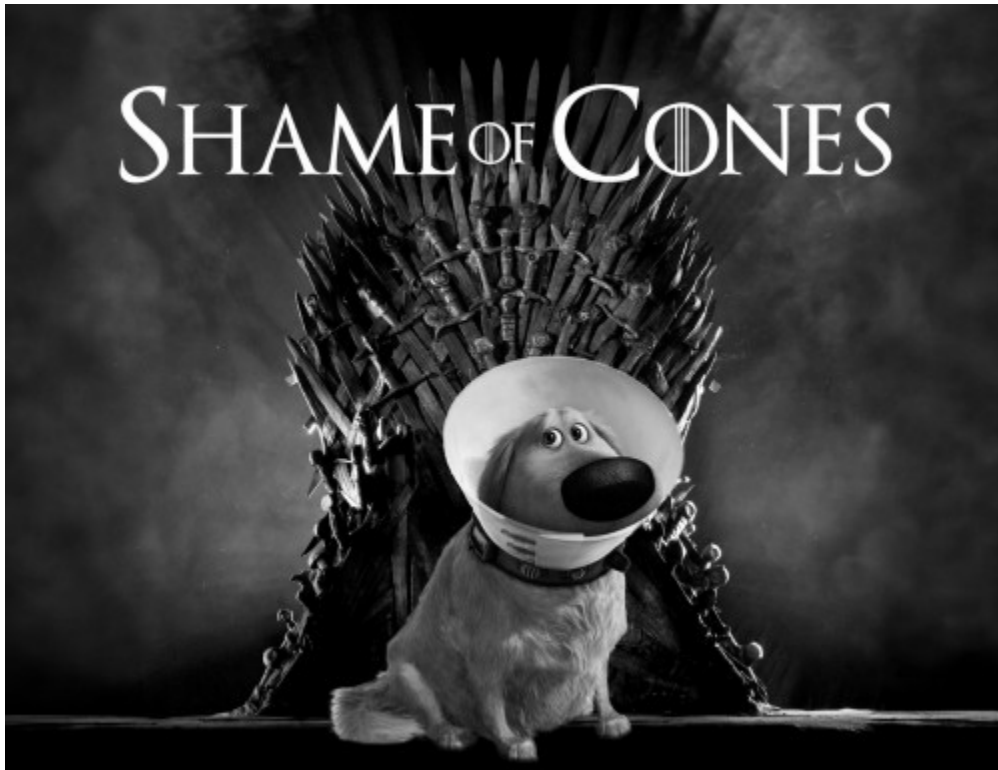# Carmalt Forceps

(for clamping large vessels/structures)






# Sutures



# Types of Suture

- Absorbable- no need to remove
  - Gut
  - Vicryl
  - PDS
- Non-Absorbable- must remove
  - Nylon
  - Silk
- Monofilament
  - Used to close delicate tissue
  - Used to prevent reactions
  - Used to prevent infection
- Multifilament
  - Used to provide better knot security
  - Causes much more inflammation
  - For sterile surgical sites only
  - More apt to cause infection



# Suture Sizes

USP (United States Pharmacopoeia)

5..4..3..2..1..0..2/0..3/0..4/0..5/0..6/0..7/0..8/0..9/0..10/0..11/0





General

**Thick**

Syneture®

Thin

# Needle Choices

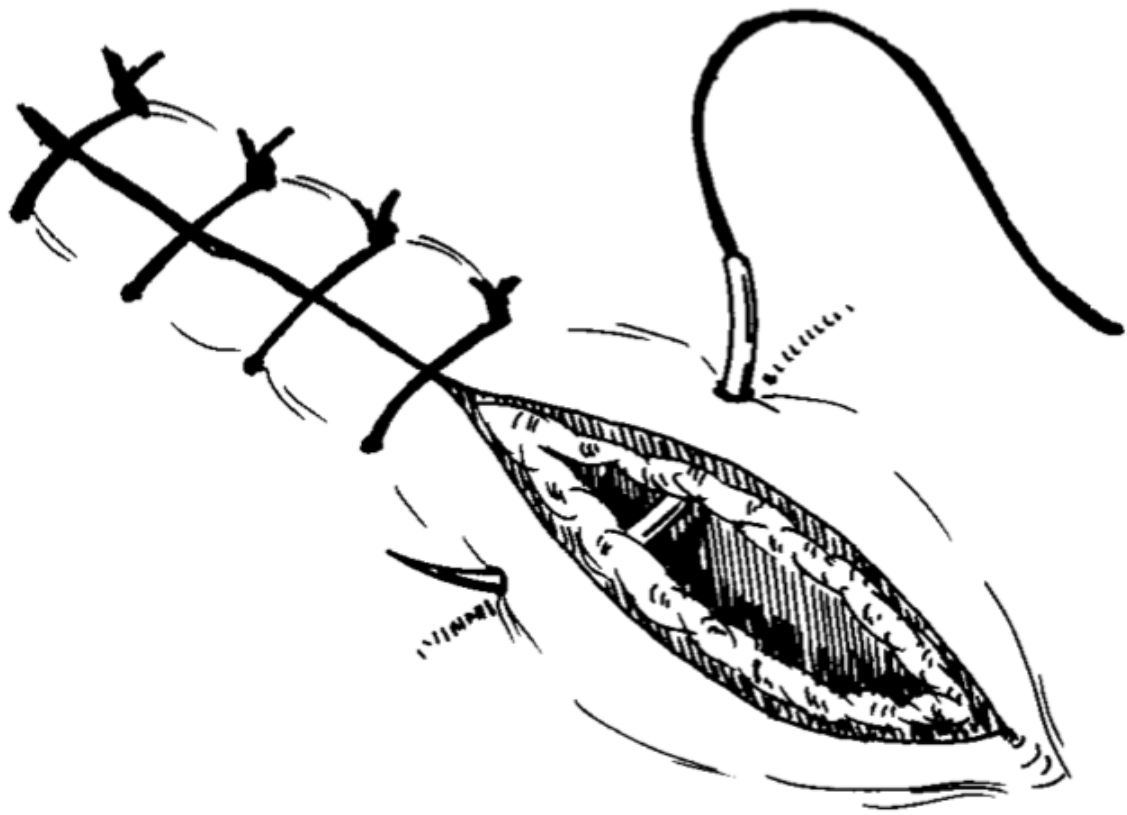
	<b>Taper-Point</b>	<ul style="list-style-type: none"> <li>•Suited to soft tissue</li> <li>•Dilates rather than cuts</li> </ul>
	<b>Reverse cutting</b>	<ul style="list-style-type: none"> <li>•Very sharp</li> <li>•Ideal for skin</li> <li>•Cuts rather than dilates</li> </ul>
	<b>Conventional Cutting</b>	<ul style="list-style-type: none"> <li>•Very sharp</li> <li>•Cuts rather than dilates</li> <li>•Creates weakness allowing suture tearout</li> </ul>
	<b>Taper-cutting</b>	<ul style="list-style-type: none"> <li>•Ideal in tough or calcified tissues</li> <li>•Mainly used in Cardiac &amp; Vascular procedures.</li> </ul>

Syneture

# Suture Patterns

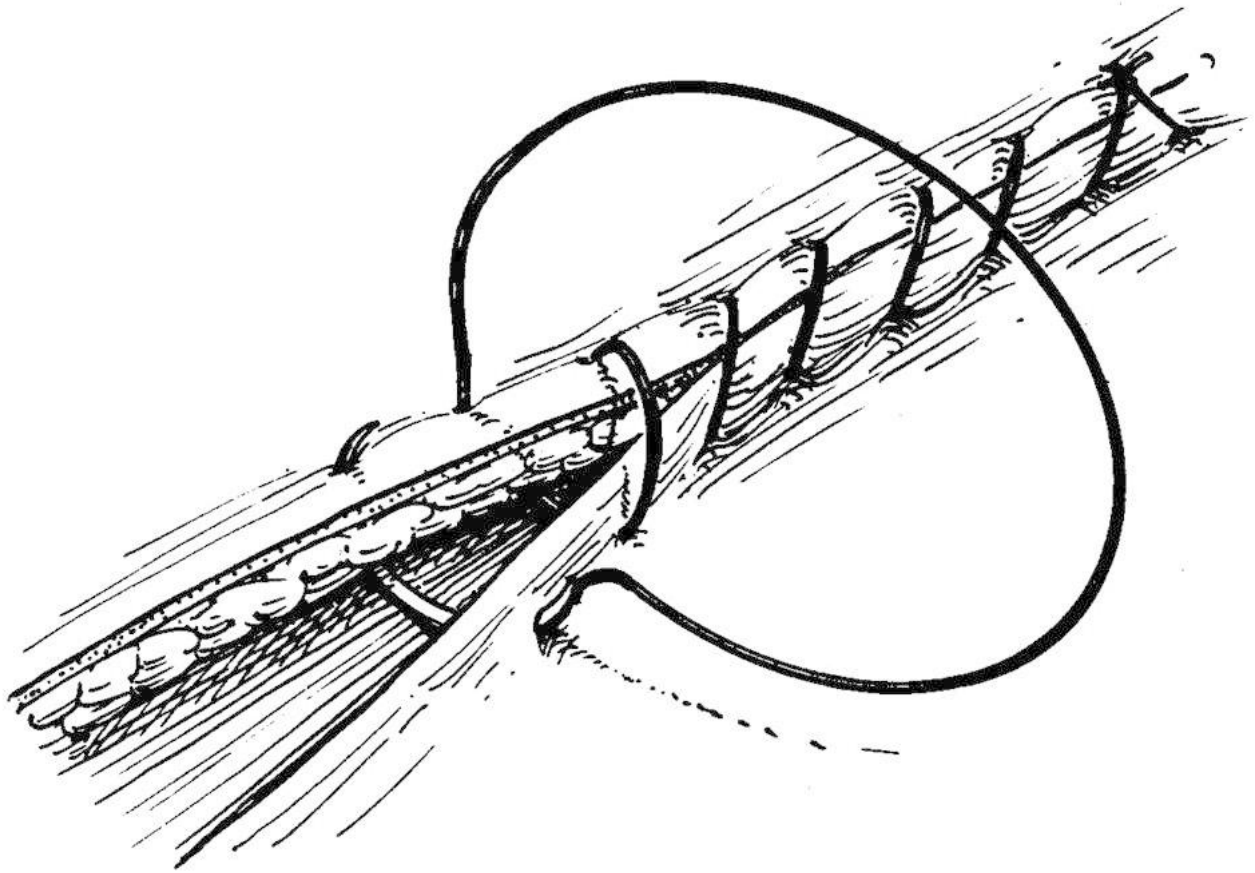
- Simple interrupted
- Simple continuous
- Horizontal Mattress
- Vertical Mattress
- Cruciate
- Subcuticular

# Simple Interrupted

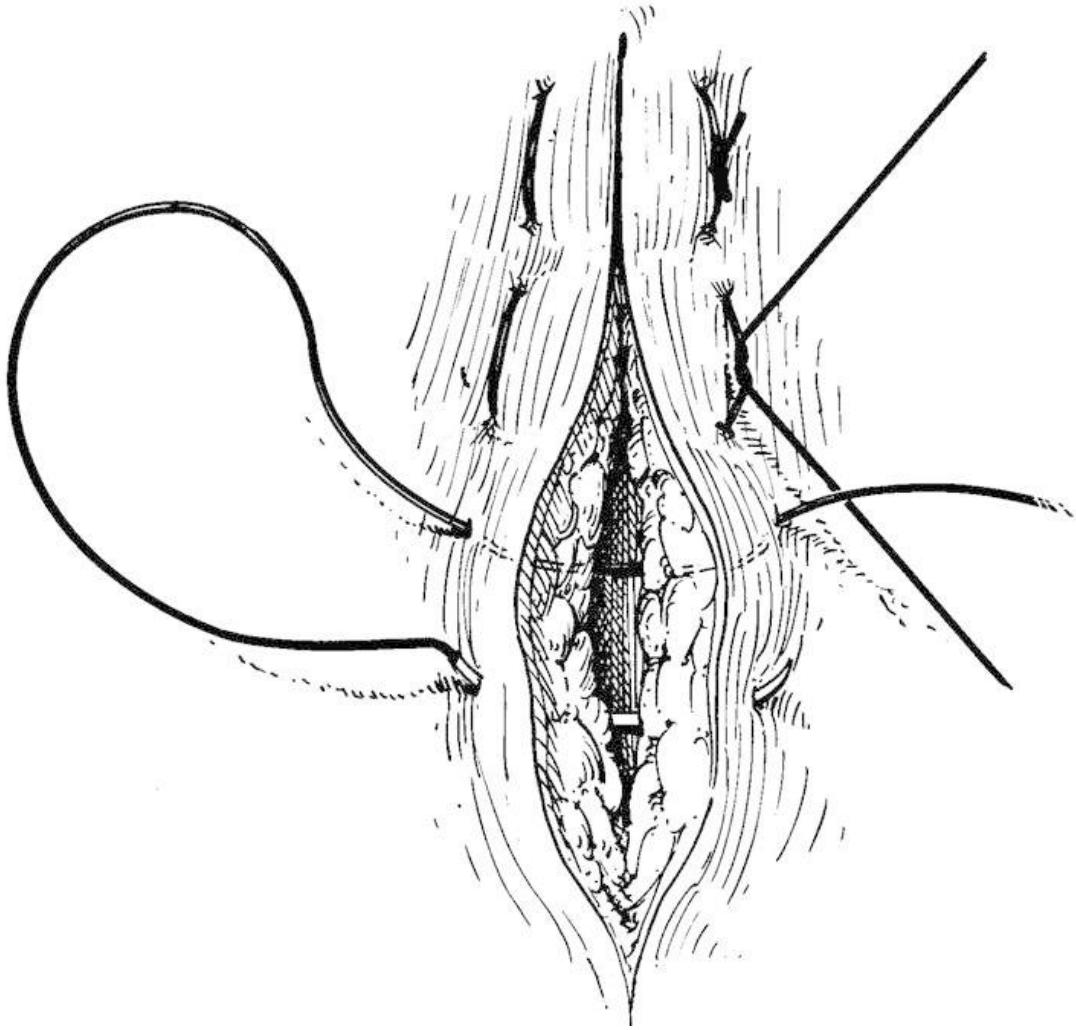




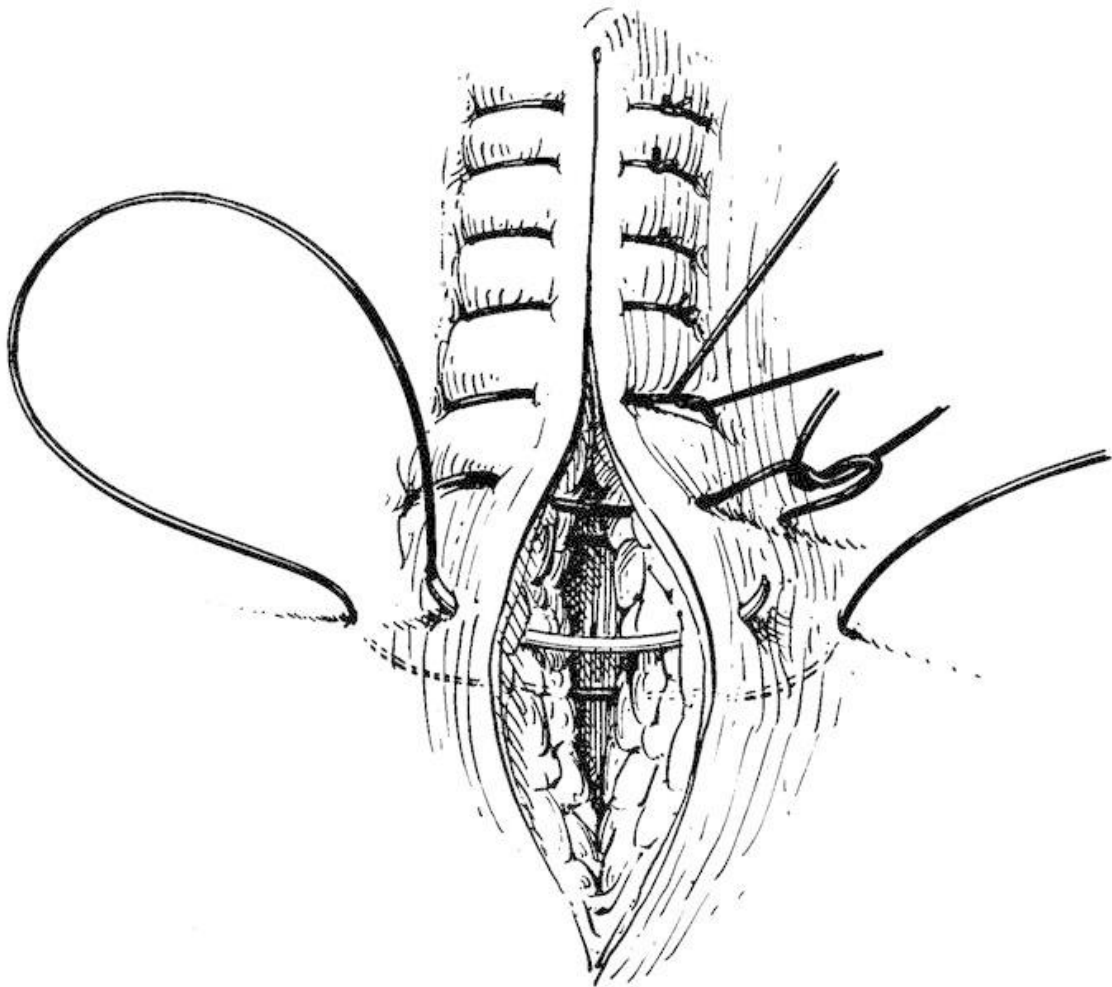
# Simple Continuous



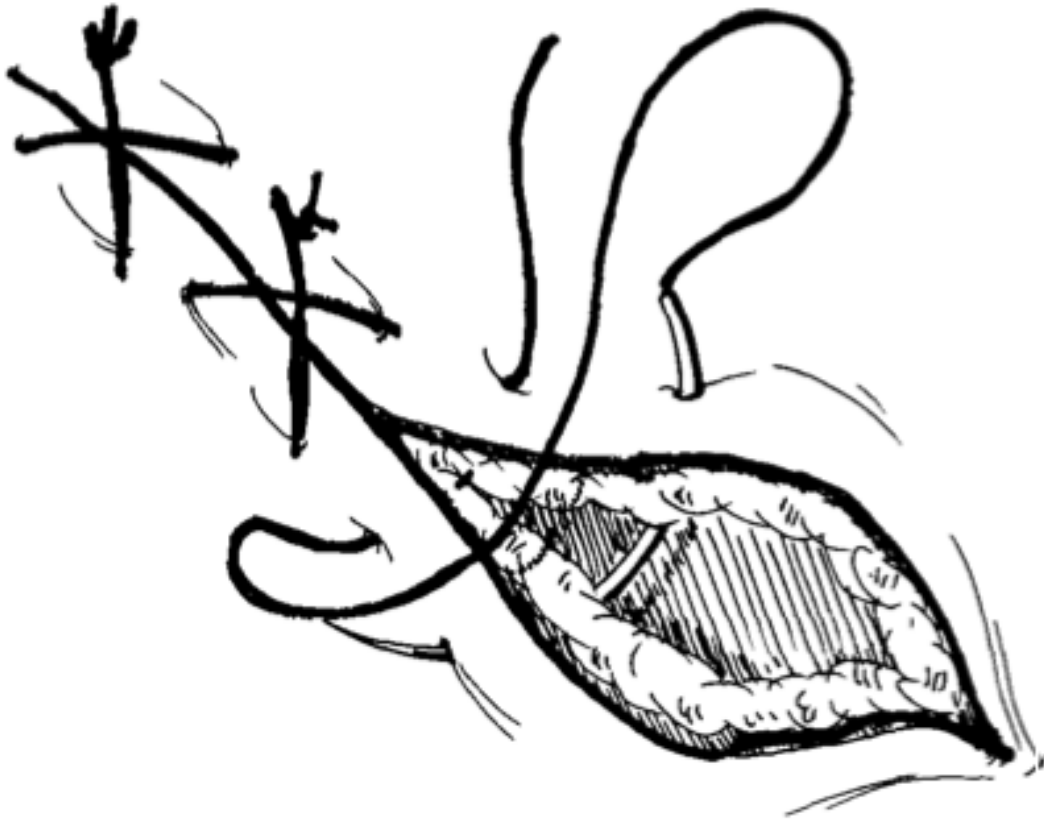# Horizontal Mattress



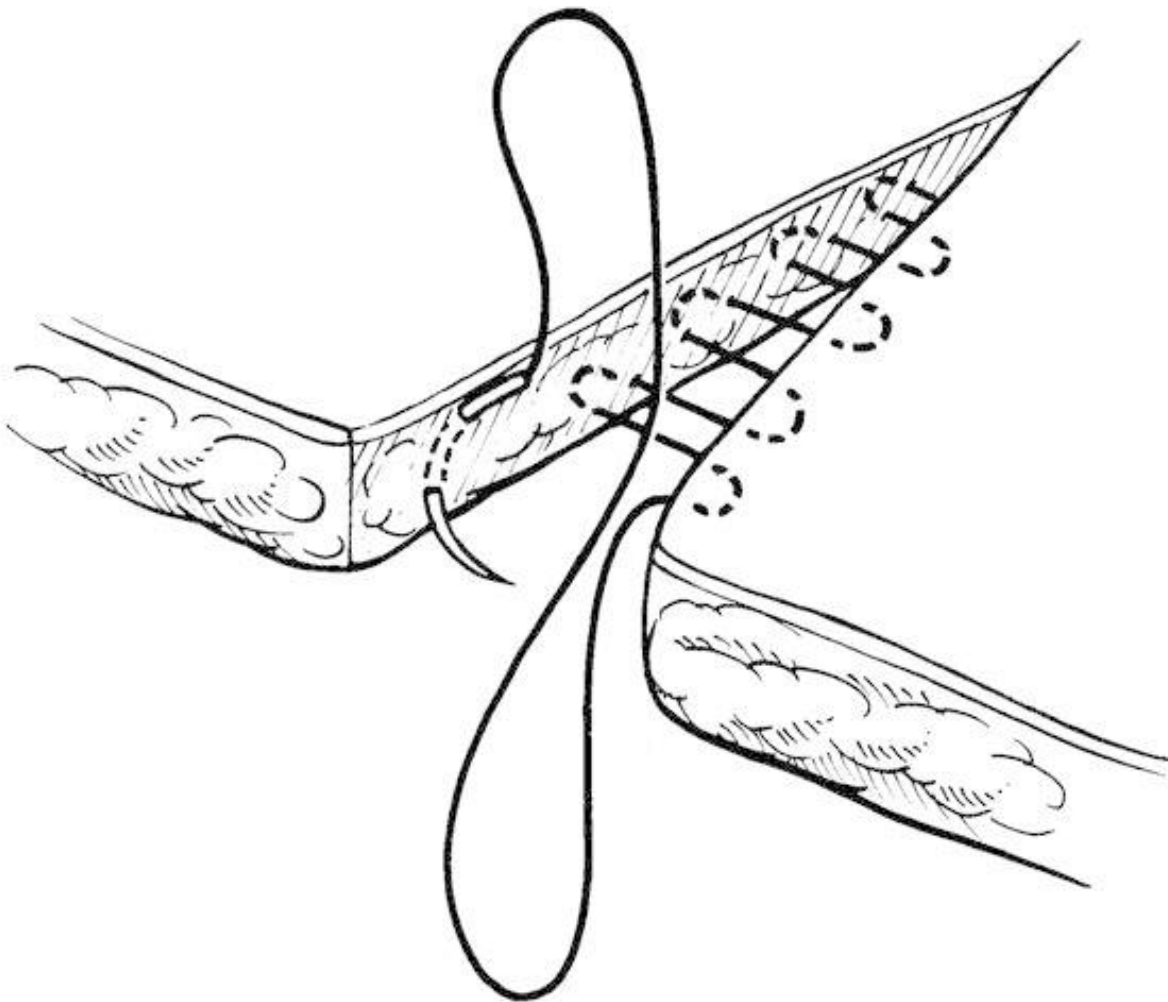
# Vertical Mattress



# Cruciate

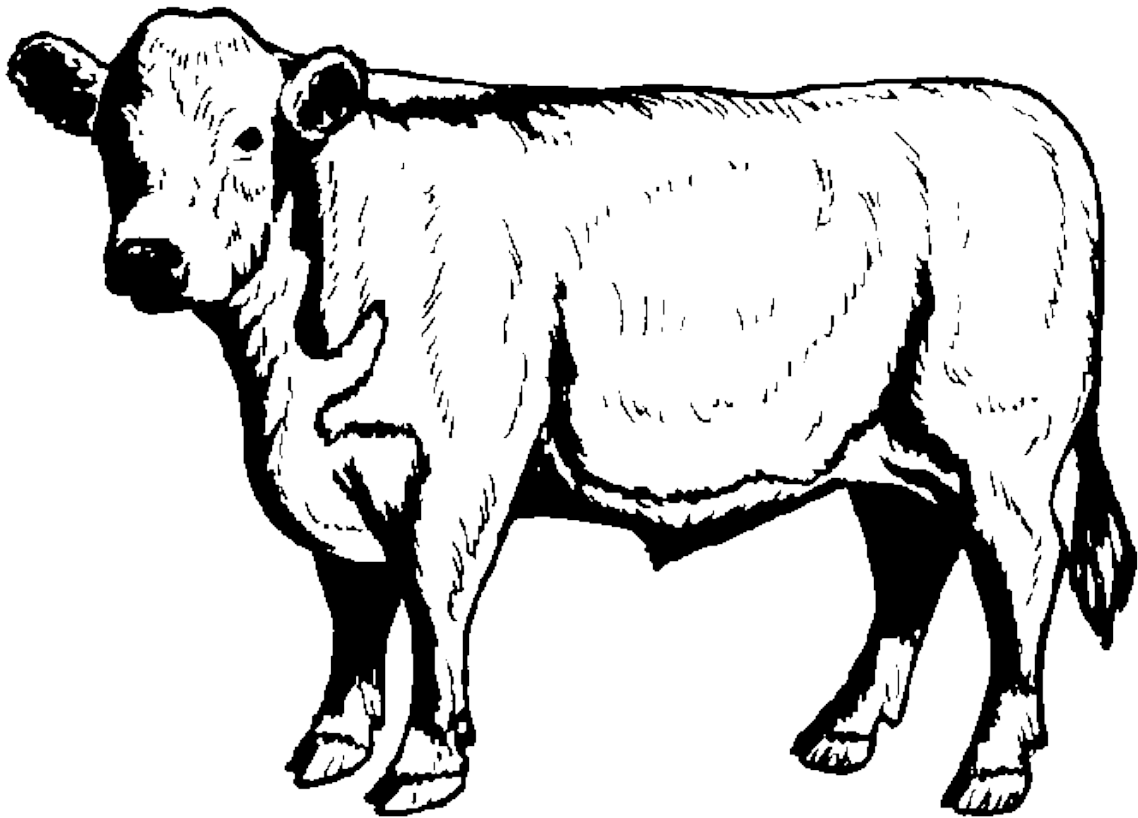


# Subcuticular





# Cattle



# Cattle Exam

## Vital Signs

- Heart rate 40-70 beats per minute
- Breathing rate 18-30 breaths per minute
- Body Temperature 100.4-103.1°F

## Examination

- Body condition and lameness score
- Eyes, mouth (teeth and gums) and hindquarters
- Reproductive organs
- Record vital signs
- Vaccinate and/or treat with medicine

## Common Problems

- Conjunctivitis and/or corneal ulcers
- External parasites
- Lameness
- Diarrhea (parasite, bacterial, viral or nutritional)
- Plant toxicity (if on pasture)



# Beef Cattle Body Condition Score

<b>Table 1. Visual indicators for body condition scores</b>									
	<b>Body Condition Score (BCS)</b>								
<b>Reference point</b>	<b>1</b>	<b>2</b>	<b>3</b>	<b>4</b>	<b>5</b>	<b>6</b>	<b>7</b>	<b>8</b>	<b>9</b>
Physically weak	yes	no	no	no	no	no	no	no	no
Muscle atrophy	yes	yes	slight	no	no	no	no	no	no
Outline of spine visible	yes	yes	yes	slight	no	no	no	no	no
Outline of ribs visible	all	all	all	3-5	1-2	0	0	0	0
Outline of hip & pin bones visible	yes	yes	yes	yes	yes	yes	slight	no	no
Fat in brisket and flanks	no	no	no	no	no	some	full	full	extreme
Fat udder & patchy fat around tail head	no	no	no	no	no	no	slight	yes	extreme

*Source: Modified from Pruitt, 1994.*

# Cattle Lameness Score

## STEP OP™



0

### Normal

Stands and walks normally. Hind feet land almost exactly in same spot as fore feet.



1

### Mildly Lamé

Shortened stride, head dropped slightly. No limp when walking.



2

### Moderately Lamé

Slight head bob when walking. Head is dropped and back arched when standing.

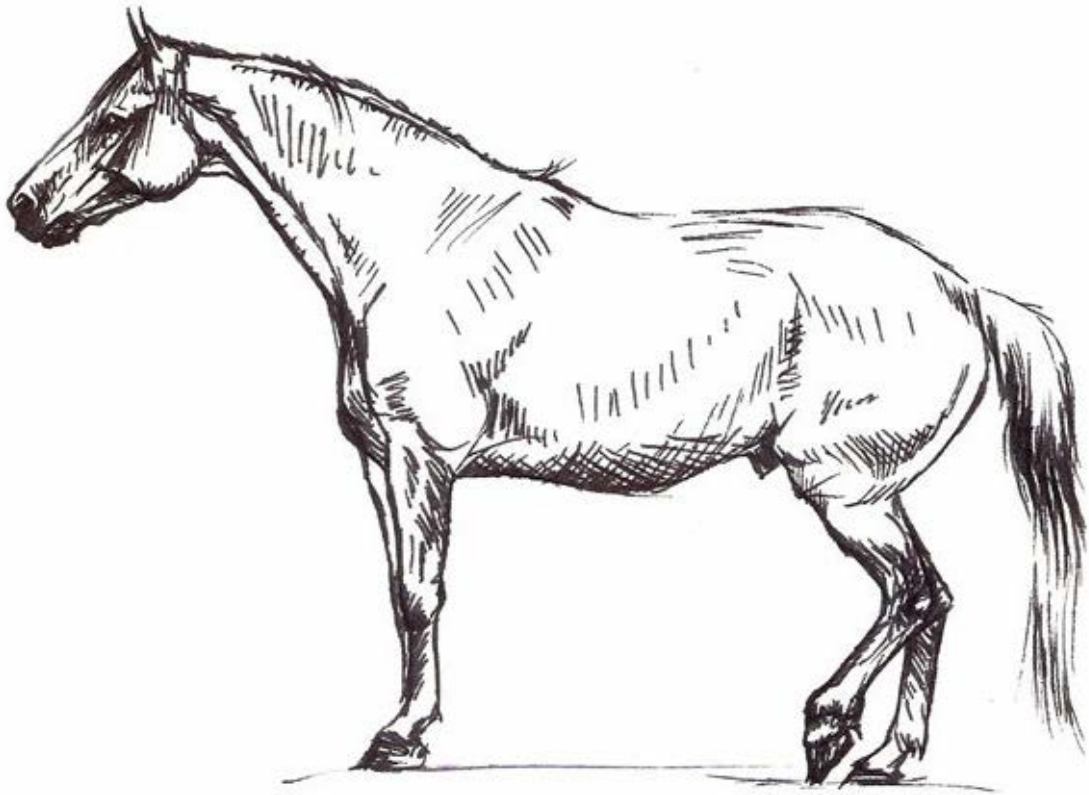


3

### Severely Lamé

Constant arched back and head bob while walking. Great difficulty moving.

# Horse



# Horse Exam

## Vital Signs

- Heart Rate 30 to 40 beats per minute
- Breathing Rate 8 to 15 breaths per minute
- Body Temperature 99-100.5°F

## Examination

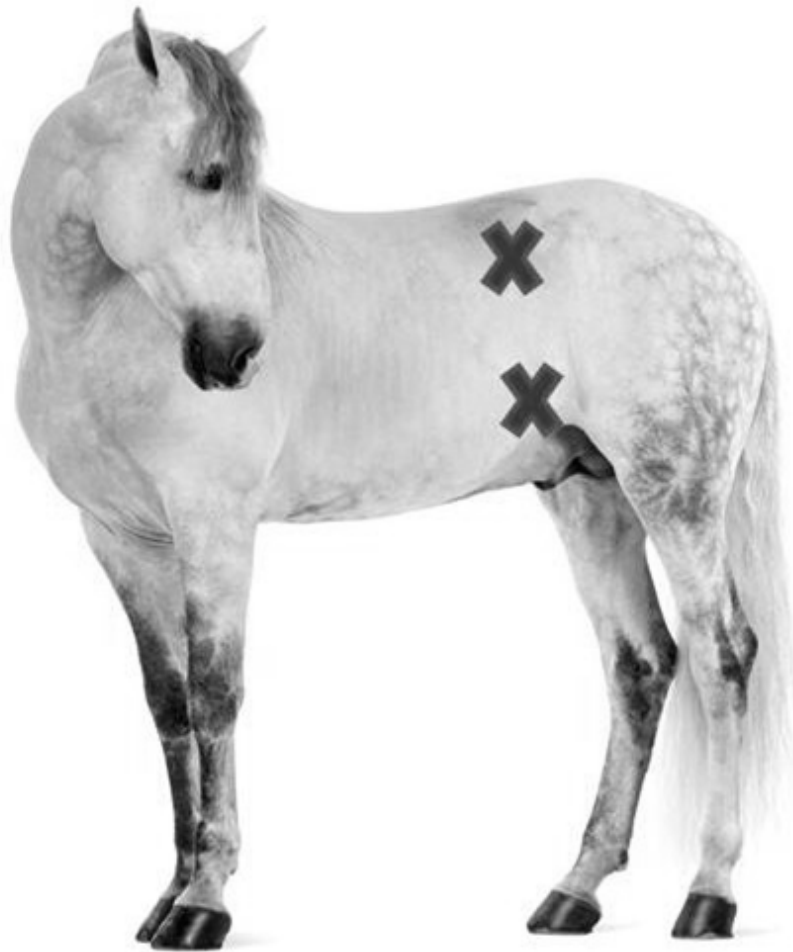- Body condition and lameness score
- Eyes, mouth (teeth and gums), skin and hooves
- Reproductive organs
- Listen to gut sounds
- Record vital signs
- Vaccinate and/or treat

## Common Problems

- Teeth (lots of wear and tear)
- Eyes
- Hooves
- Gastrointestinal system

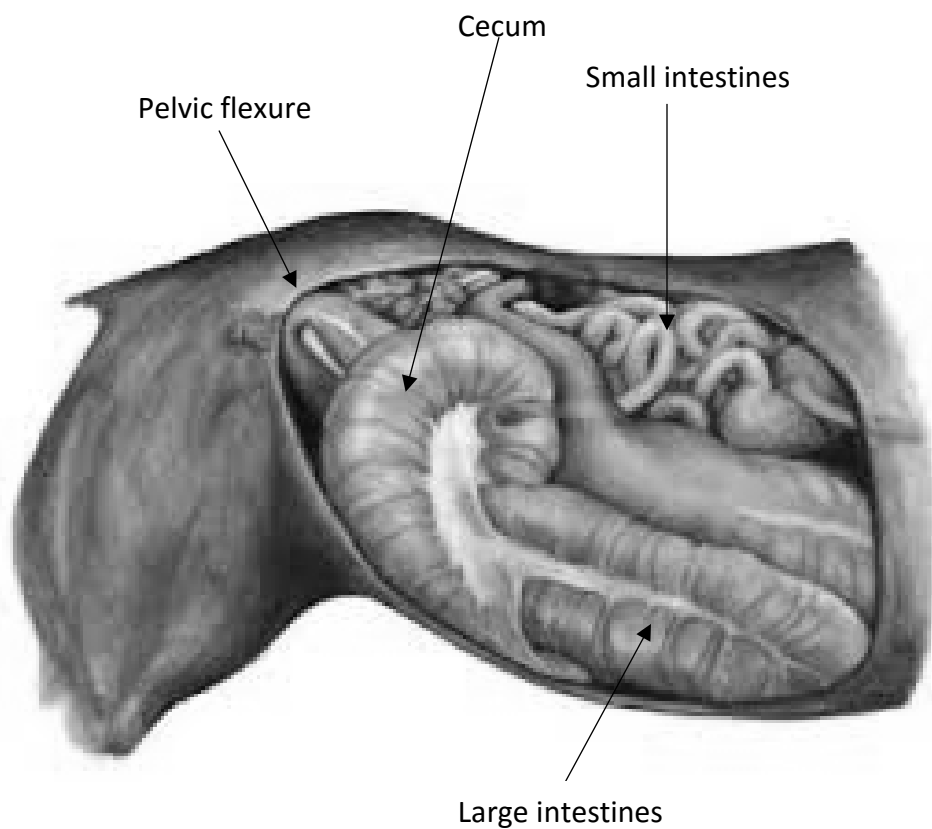
# Horse Gut Auscultation

- Too much sound= hypermotility
- Little sound= hypomotility
- No sound= ileus
- Left top is small intestine, left bottom is large intestine
- Right top is cecum, right bottom is large intestine




# Why is the Horse Gut a Problem?

- The large colon has many twists and turns
- The small pelvic flexure is a common impaction site
- Horses cannot vomit
- Horses with a slow gut get constipated



# Pig



# Pig Exam

## Vital Signs

- Heart Rate 60 to 100 beats per minute
- Breathing Rate 8 to 18 breaths per minute
- Body Temperature 100.4-104°F

## Examination

- Body condition
- Eyes, mouth (teeth and gums), skin and hooves
- Reproductive organs
- Record vital signs
- Vaccinate and/or treat

## Common Problems

- Internal parasites
- External parasites
- Lameness
- Respiratory disease
- Diarrheal disease




# Visual Signs of a Problem

- Eye discharge
- Runny nose
- Slobbery mouth
- Droopy ears
- Rough fur
- Coughing or wheezing
- Kicking at belly
- Swollen mammary glands
- Limping +/- feet wounds
- Swollen joints
- Discharge/swelling at vulva
- Diarrhea
- Biting at tail
- Thin at back area





# Sheep



# Sheep Exam

## Vital Signs

- Heart Rate 70 to 80 beats per minute
- Breathing Rate 15 to 30 breaths per minute
- Body Temperature 101-103.5°F

## Examination

- Body condition
- Eyes, mouth (teeth and gums), skin and hooves
- Reproductive organs
- Record vital signs
- Vaccinate and/or treat

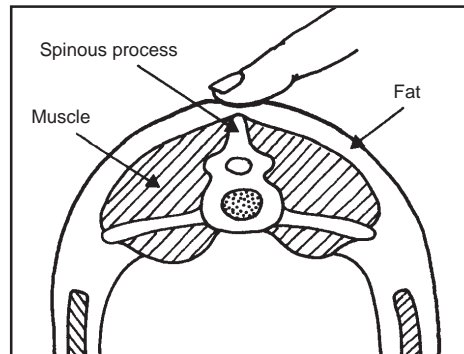
## Common Problems

- Internal parasites\*\*\*
- External parasites
- Hoof problems
- Joint problems
- Reproduction problems

# Body condition scoring of sheep

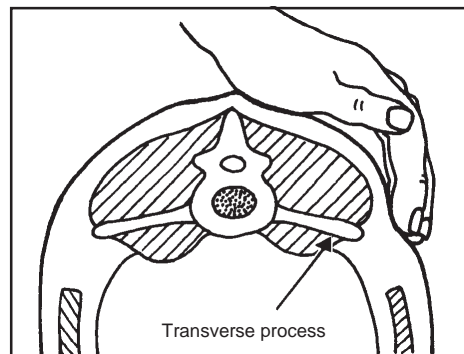
Sheep are often too fluffy to see the BCS!

1.



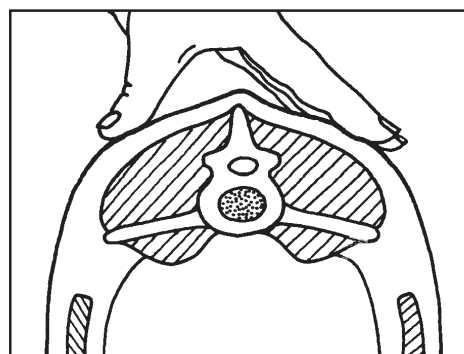
*Feel for the spine in the center of the sheep's back, behind its last rib and in front of its hip bone.*

2.



*Feel for the tips of the transverse processes.*

3.



*Feel for fullness of muscle and fat cover.*

### Condition 1 (Emaciated)

Spinous processes are sharp and prominent. Loin eye muscle is shallow with no fat cover. Transverse processes are sharp; one can pass fingers under ends. It is possible to feel between each process.

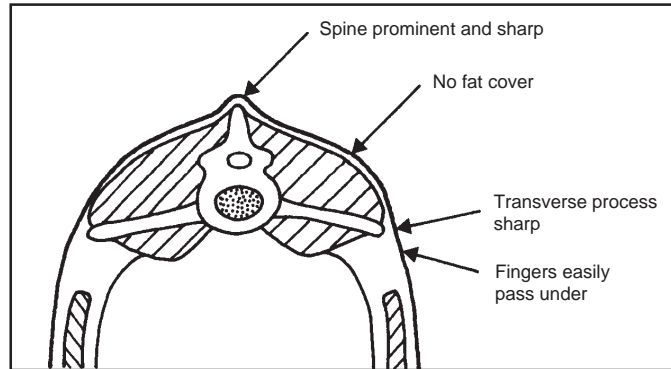


Figure 4.—Condition 1

### Condition 2 (Thin)

Spinous processes are sharp and prominent. Loin eye muscle has little fat cover but is full. Transverse processes are smooth and slightly rounded. It is possible to pass fingers under the ends of the transverse processes with a little pressure.

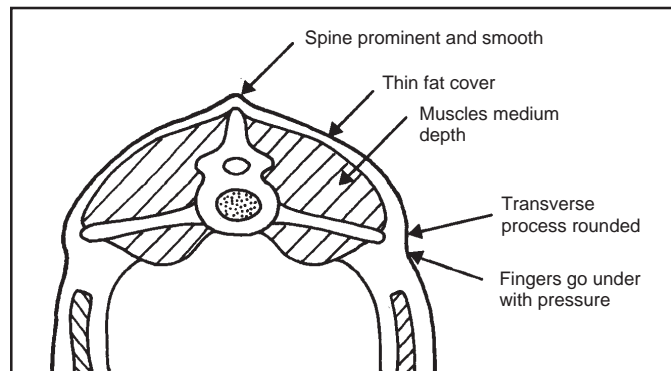


Figure 5.—Condition 2

**Condition 3 (Average)** Spinous processes are smooth and rounded and one can feel individual processes only with pressure. Transverse processes are smooth and well covered, and firm pressure is needed to feel over the ends. Loin eye muscle is full with some fat cover.

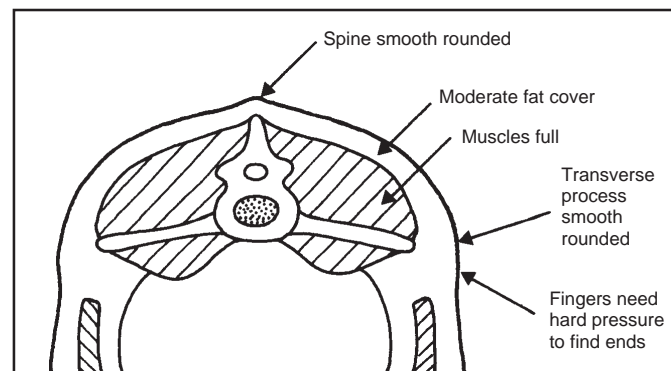


Figure 6.—Condition 3

### Condition 4 (Fat)

Spinous processes can be detected only with pressure as a hard line. Transverse processes cannot be felt. Loin eye muscle is full with a thick fat cover.

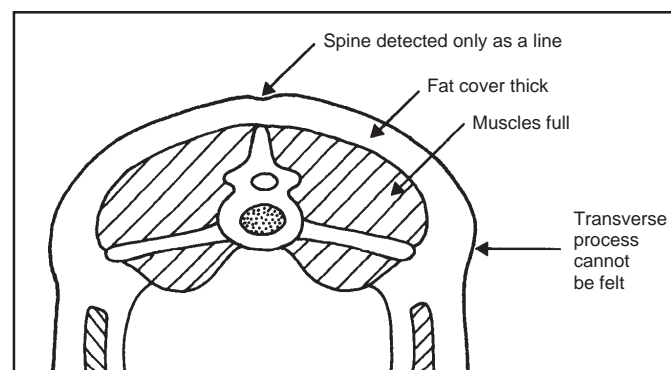


Figure 7.—Condition 4

**Condition 5 (Obese)**

Spinous processes cannot be detected. There is a depression between fat where spine would normally be felt. Transverse processes cannot be detected. Loin eye muscle is very full with a very thick fat cover.

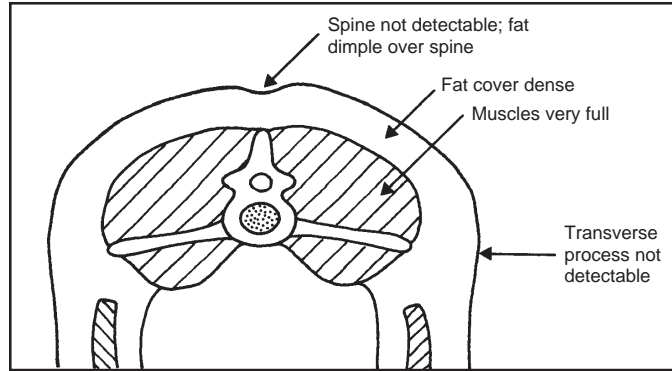
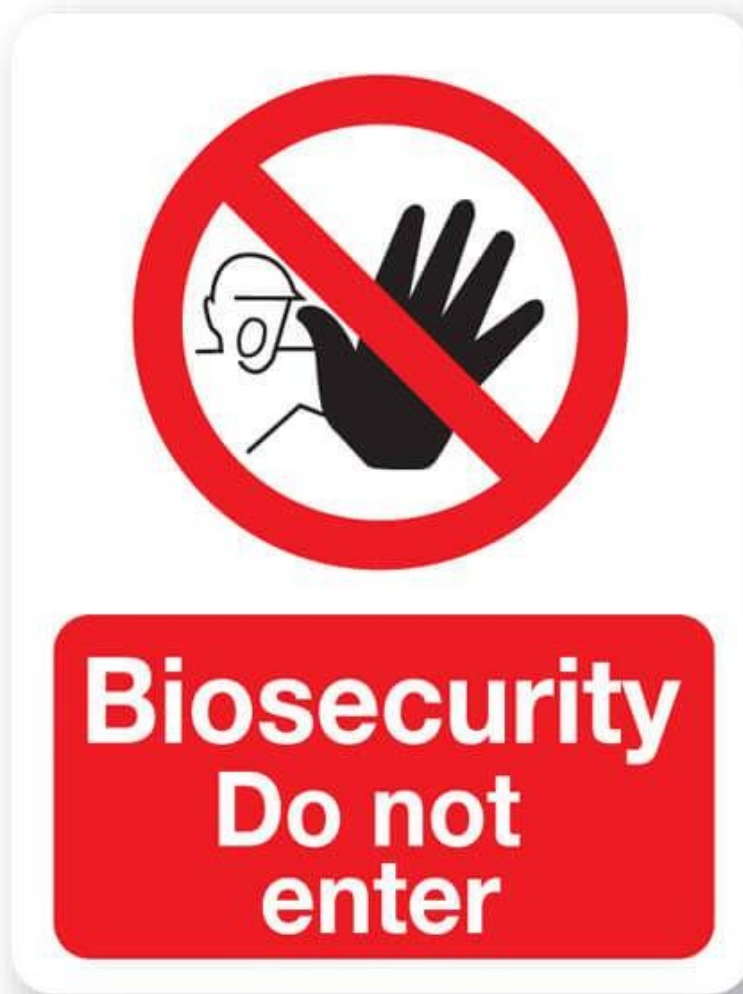

Figure 8.—Condition 5





# Biosecurity



# What is Biosecurity?

Farm biosecurity is a set of measures designed to protect a property from the entry and spread of pests and diseases. Farm biosecurity is your responsibility, and that of every person visiting or working on your property.

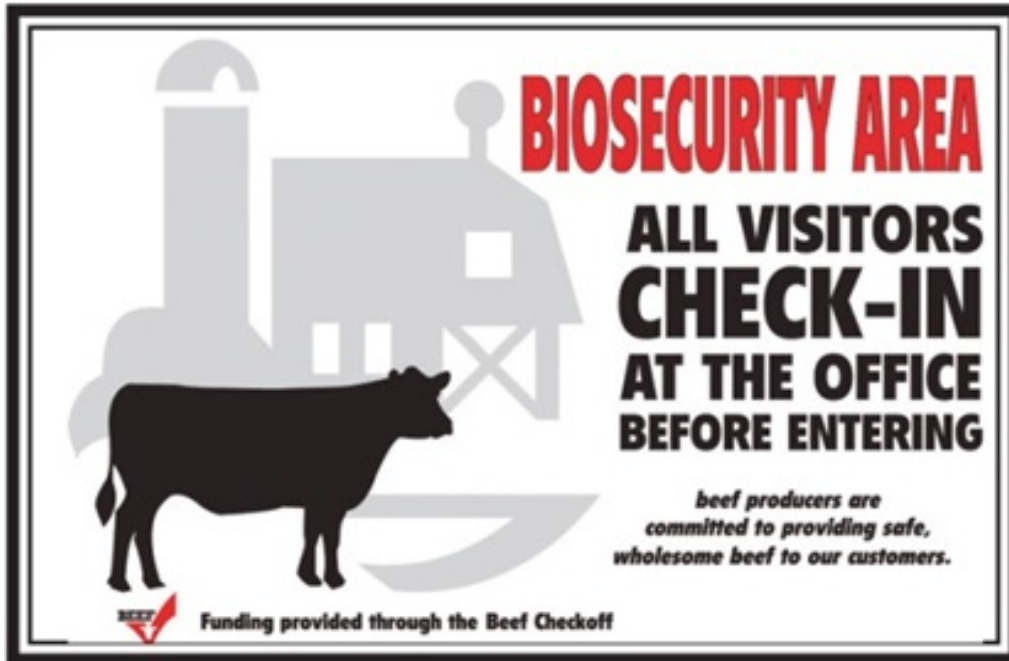


# What is risk assessment?

Risk assessment is a way of determining the presence, distribution, and severity of a given disease. Once risk areas have been identified, appropriate control measures can be enacted. Acceptable levels of risk for a farm will be determined by what products are sold or what may be sold from the farm in the future. Typically this involves meat, milk, perhaps breeding animals, embryos, etc. Understanding what diseases are important for the sale of each of these products and understanding how disease may enter and spread within animal groups is the next step. This is followed by close evaluation of methods to prevent the disease from entering the herd from sources outside the farm.

# Who is involved?

In most cases the herd veterinarian works closely with the producer to develop and start the implementation of a biosecurity plan. However, each and every person who lives, works, or visits the farm has a stake and role in the biosecurity plan. To make a biosecurity plan effective and easier to follow it is important to adopt practices that are customized to the individual farm setting and really make a difference. Not all animal groups are equally susceptible to infection and not all human activities are equally likely to contribute to disease control or potential spread.



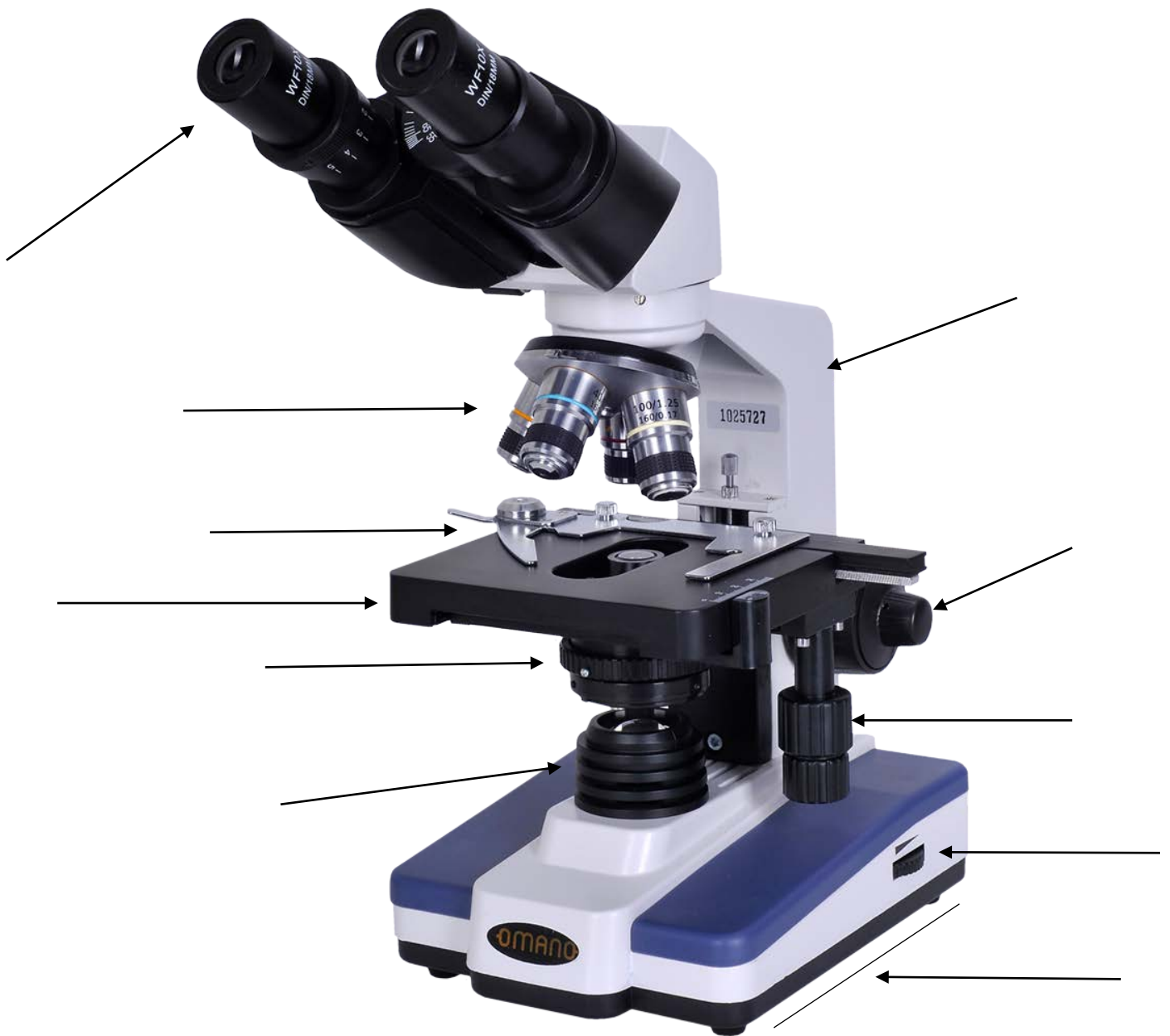\*Cooperation and promotion of a sound biosecurity plan is important for the financial health of the farm, as well as the consumer through wholesome and high quality agricultural products.



# Microscope Laboratory

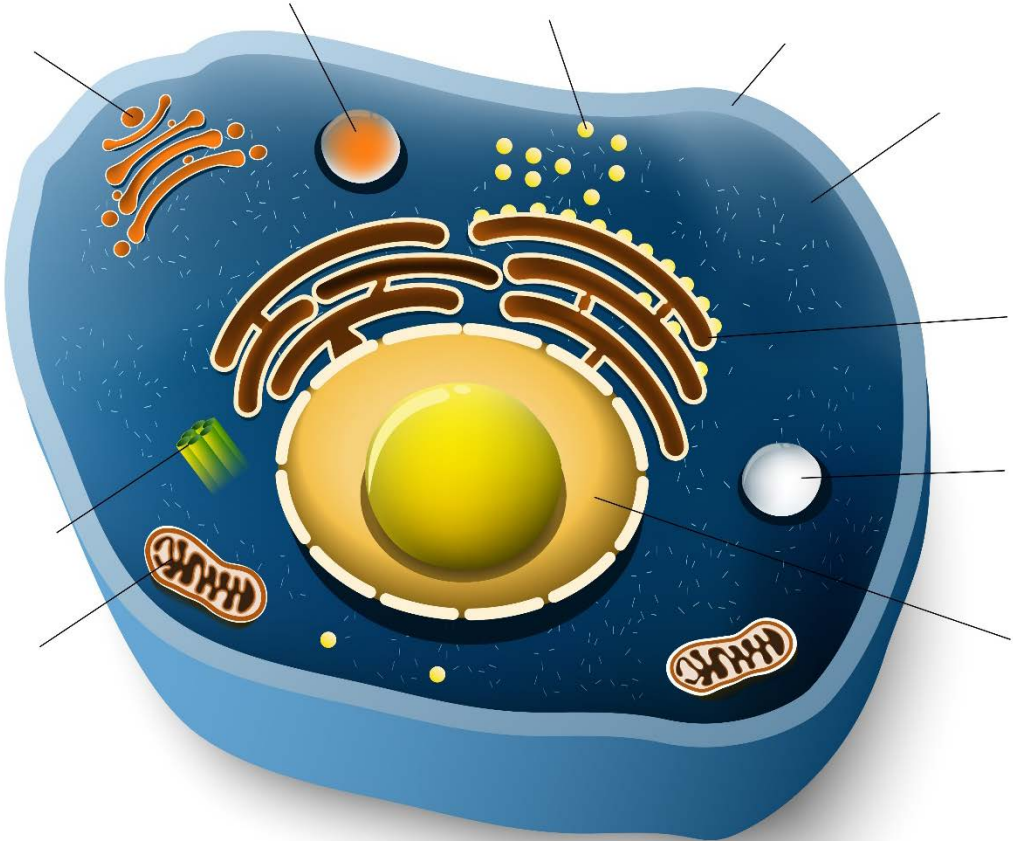


# The Compound Microscope





# The Animal Cell



# Parts of the Animal Cell

- \_\_\_\_ Nucleus
- \_\_\_\_ Membrane
- \_\_\_\_ Cytoplasm
- \_\_\_\_ Rough Endoplasmic Reticulum
- \_\_\_\_ Ribosomes
- \_\_\_\_ Golgi Apparatus
- \_\_\_\_ Centriole
- \_\_\_\_ Mitochondrion
- \_\_\_\_ Peroxisome
- \_\_\_\_ Lysosome

- a. the site of biological protein synthesis (translation)
- b. provides the main source of energy- ATP
- c. contains most of the genetic material of the cell
- d. organelle that breaks down long chain fatty acids
- e. packages proteins into membrane-bound vesicles
- f. synthesizes and exports proteins and membrane lipids
- g. the gel-like substance enclosed within the cell membrane
- h. contains enzymes that break down biomolecules
- i. structure that aid in the organization of cell division
- j. separates cell from the extracellular environment

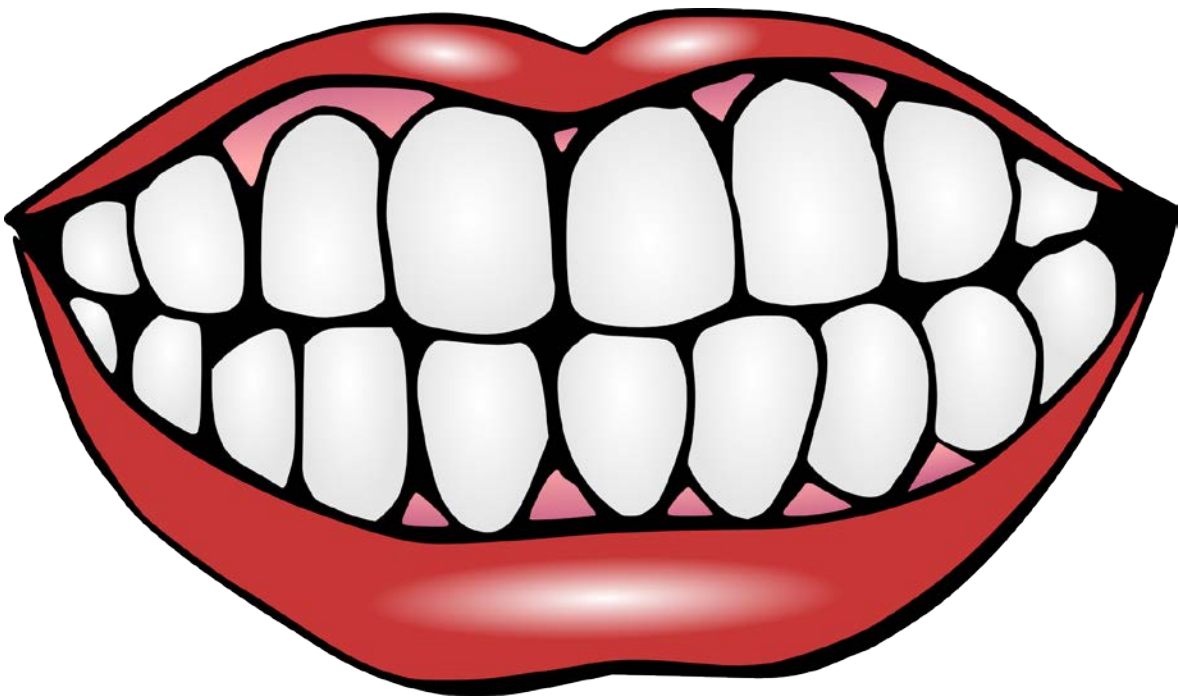# Select Cell Functions

- \_\_\_ Goblet Cell
- \_\_\_ Chief Cell
- \_\_\_ Parietal Cell
- \_\_\_ Type I Alveolar Cell
- \_\_\_ Type II Alveolar Cell
- \_\_\_ Macrophage
- \_\_\_ Neuron
- \_\_\_ Red Blood Cell
- \_\_\_ Platelet
- \_\_\_ Neutrophils

- a. transmits information by electrical and chemical signals
- b. first-responders of immune defense that create pus
- c. involved in gas exchange
- d. stops bleeding by clumping and clotting
- e. engulfs and digests cellular debris
- f. secretes hydrochloric acid
- g. delivers oxygen to body tissues
- h. secretes pulmonary surfactant
- i. secretes the digestive enzyme pepsinogen
- j. secretes mucin



# Teeth Laboratory



# Definitions

1. **Veterinary Dentistry:**

---

---

2. **Periodontal Disease:**

---

---

3. **Tartar:**

---

---

4. **Plaque:**

---

5. **Gingivitis:**

---

---

6. **Lingual:**

---

7. **Buccal:**

---

8. **Occlusal:**

---

9. **Rostral:**

---

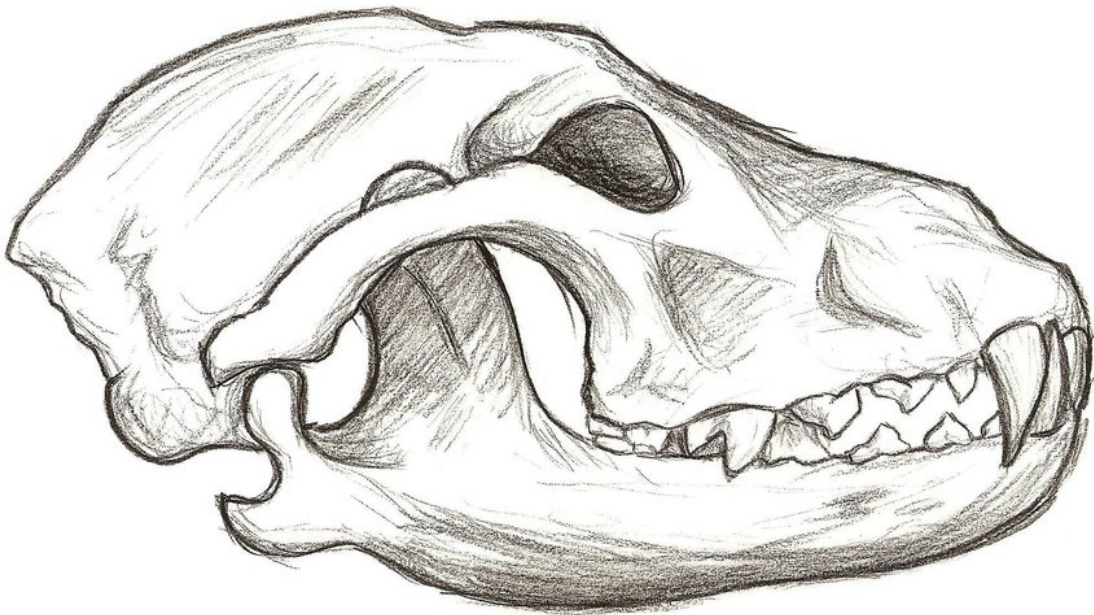10. **Caudal:**

---

# Canine Teeth

## Permanent teeth eruption:

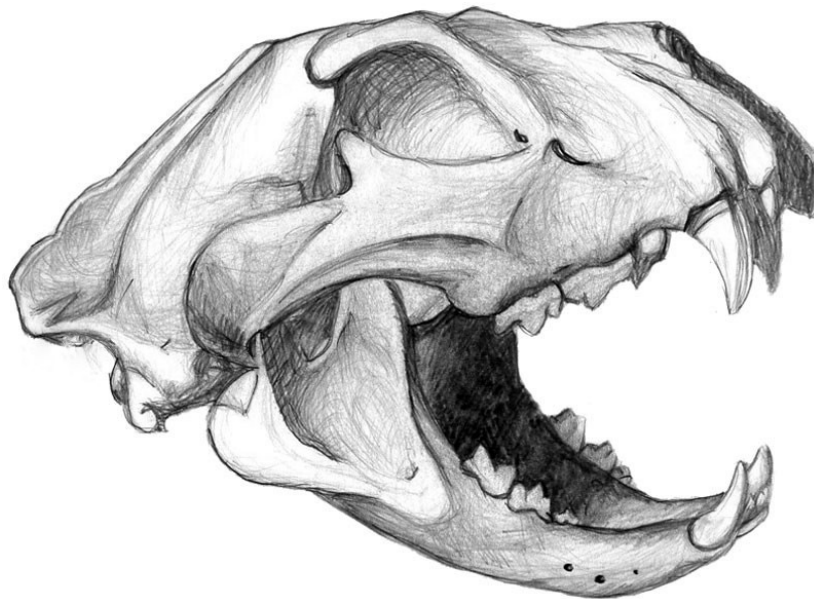
- Incisors: 105-125 days
- Canines: 125-141
- P1 : 110-150 days
- P2/P3 : 150 days
- P4 : 135-185 days (completed)
- M1 : 140-165 days
- M2 : 160-220 days
- M3 : 180-220 days



# Feline Teeth

## Permanent teeth eruption:

- Incisors : 103-135 days
- Canines : 149-153 days
- Premolars : 150-174 days
- Molars : 130-162 days

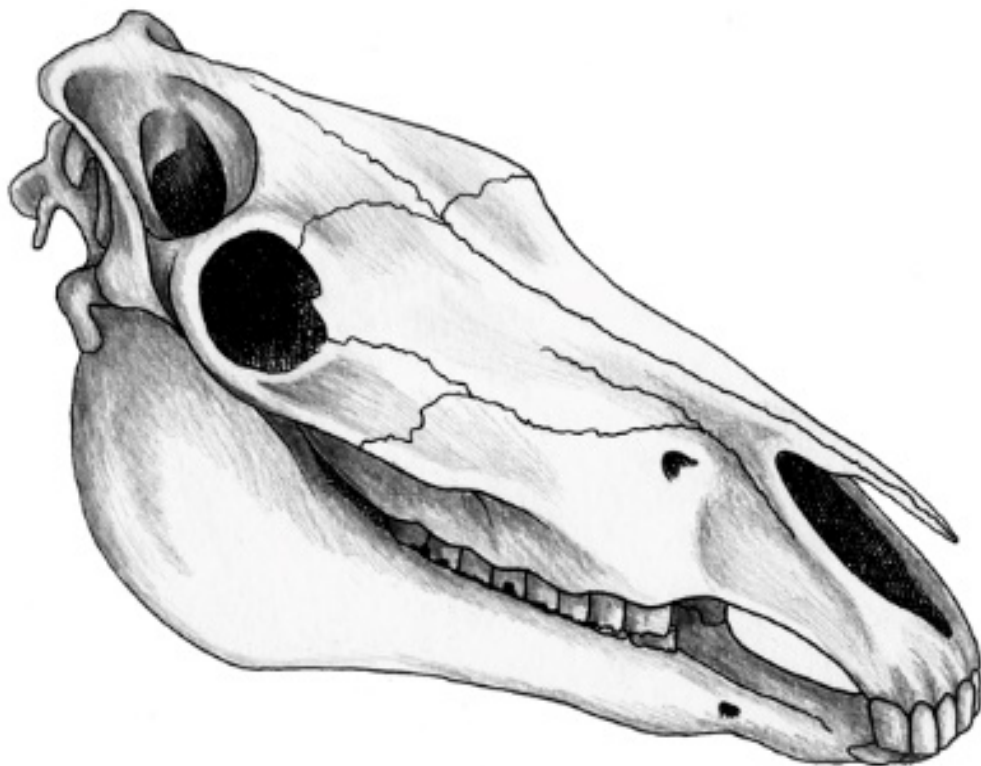



# Horse Teeth

## Permanent teeth eruption:

- 1<sup>st</sup> Incisors: 2 ½ years
- 2<sup>nd</sup> Incisors: 3 ½ years
- 3<sup>rd</sup> Incisors: 4 ½ years
- Canines: 4 to 5 years
- P1 (wolf tooth): 5 to 6 months
- P2: 2 ½ years
- P3: 3 years
- P4: 4 years
- M1: 9 to 12 months
- M2 : 2 years
- M3 : 3 ½ to 4 years



# Dental Problems

## **Congenital Malformation**

- Retrognathism (overbite, parrot mouth or dorkfish)
- Prognathism (underbite or monkey mouth)

## **Retained Deciduous Teeth**

- Canine teeth are most commonly retained in carnivores
- Retained teeth will damage permanent teeth

## **Periodontal Disease**

- Stage I
- Stage II
- Stage III
- Stage IV

## **Fractures**

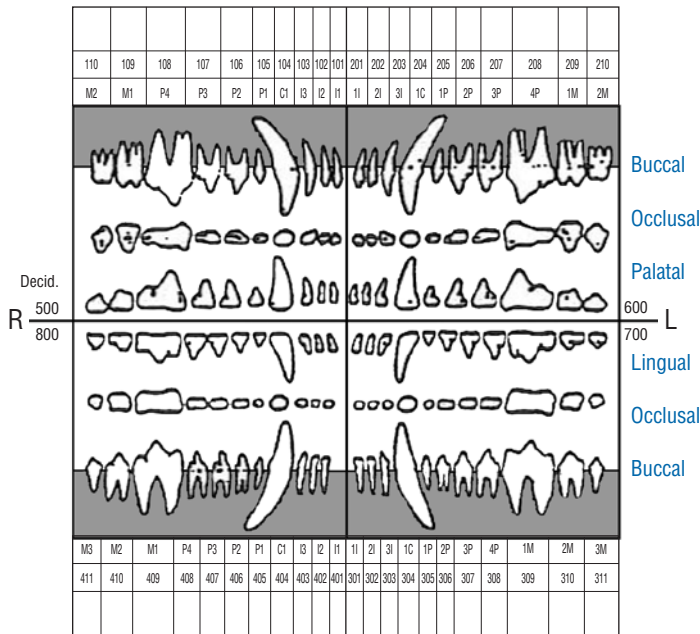
- Enamel only
- Enamel and pulp
- Root
- Jaw bone

## **Malformation from chewing**

- Hooks
- Ramps
- Enamel points
- Wavemouth

# CANINE DENTAL EXAMINATION

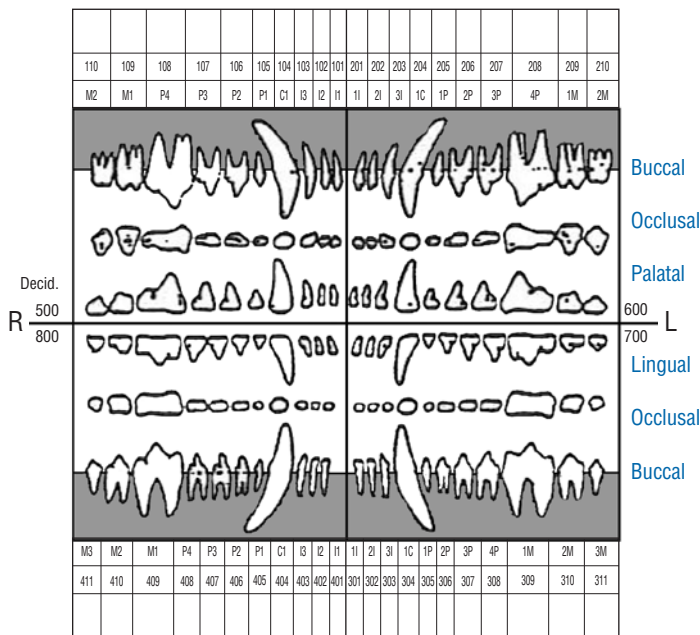
## Examination



Stamp clinic information below:

TREATMENT		OTHER	
Scaling		Rads:	1 2 3
Polishing			
Extraction			
Comments:			

## Treatment



Last prophyl (months ago):	
Home care:	
Brush: Y N	Material:
Oral rinse: Y N	Material:
Diet: dry moist other	
Oral Habits: chews hard objects	does not chew
	(circle one)
Extraoral facial symmetry	N A
Lymph nodes	N A
Buccal mucosa	N A
Tongue	N A
Palate	N A
Tonsils	N A
Pharynx	N A
Salivary flow	N A
	A = abnormal N = normal

## Abbreviations

<b>BE</b> Biopsy, excisional	<b>G</b> Granuloma	<b>PE</b> Pulp exposed	<b>ST</b> Stomatitis
<b>BI</b> Biopsy, incisional	<b>GI</b> Gingival index (1, 2, 3)	<b>PI</b> Plaque index (1, 2, 3)	<b>T/A</b> Tooth avulsed
<b>CA</b> Caries	<b>GH</b> Gingival hyperplasia	<b>PP</b> Periodontal pocket	<b>T/I</b> Tooth impacted
<b>CI</b> Calculus index (1, 2, 3)	<b>GR</b> Gingival recession	<b>PRO</b> Periodontal prophylaxis	<b>TR</b> Tooth resorption (1, 2, 3, 4, 5)
<b>CR</b> Crown restoration	<b>MI</b> Mobility index (1, 2, 3)	<b>R/C</b> Composite filling	<b>X</b> Simple closed extraction
<b>FI</b> Furcation index (1, 2, 3)	<b>OM</b> Oral mass	<b>RD</b> Retained deciduous	<b>XS</b> Nonsurgical extraction with tooth sectioning
<b>FX</b> Fractured tooth or jaw	<b>PC</b> Pulp capping	<b>RRT</b> Retained root tip	<b>XSS</b> Surgical extraction

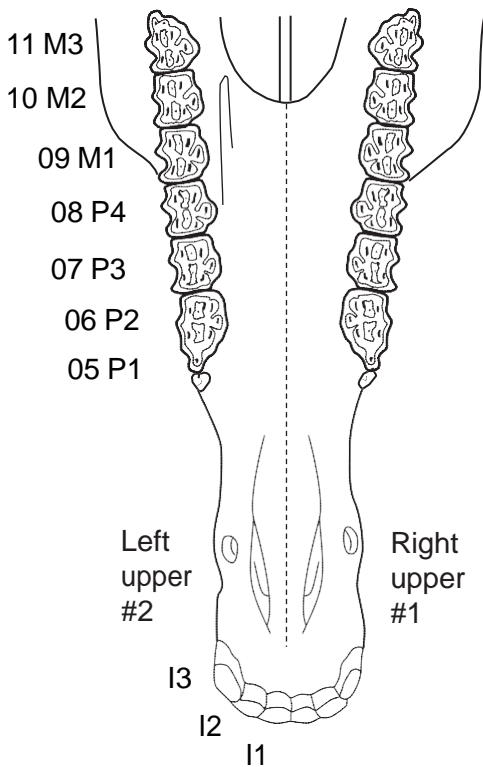
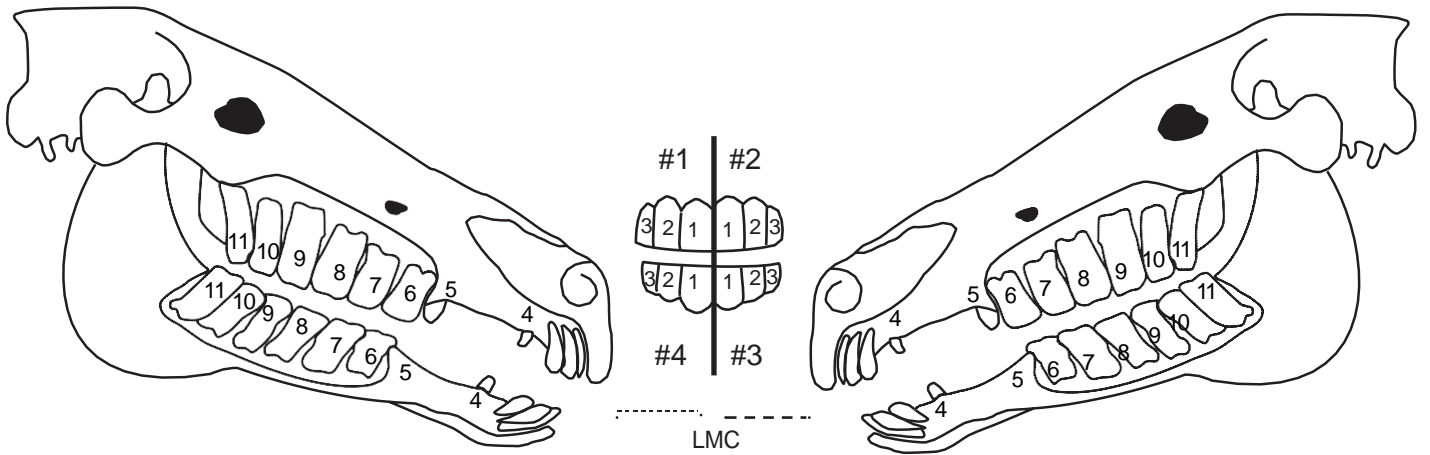


# EQUINE DENTAL EXAMINATION



**VETERINARIAN:**

DATE	HORSE	AGE	SEX	BREED
COLOUR	CONDITION	TIME OWNED		USE
OWNER		HISTORY		AT
ADDRESS			TEL	



**Comments**

.....

.....

.....

.....

.....

.....

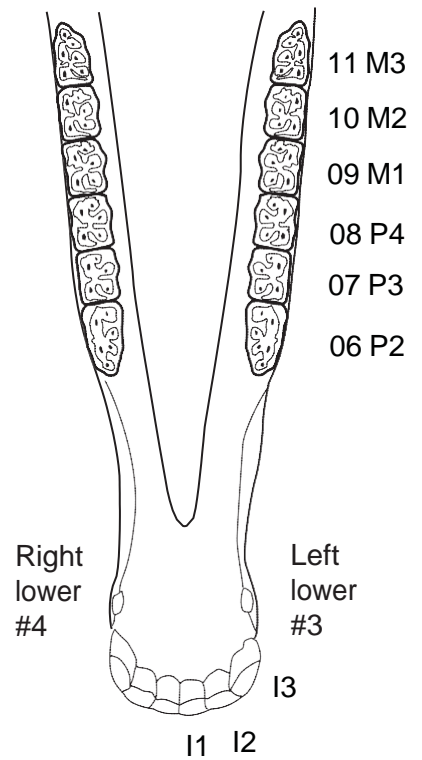
.....

.....

.....

.....

.....



Sedation: .....

Re-examination Recommended .....

# 2013 AAHA Dental Care Guidelines for Dogs and Cats\*

Steven E. Holmstrom, DVM, DAVDC, Jan Bellows, DVM, DAVDC, DABVP, Stephen Juriga, DVM, DAVDC, Kate Knutson, DVM, Brook A. Niemiec, DVM, DAVDC, Jeanne Perrone, CVT, VTS (Dentistry)

## ABSTRACT

Veterinary dentistry is constantly progressing. The purpose of this document is to provide guidelines for the practice of companion animal dentistry for the veterinary profession. Dental care is necessary to provide optimum health and optimize quality of life. Untreated diseases of the oral cavity are painful and can contribute to local and systemic diseases. This article includes guidelines for preventive oral health care, client communication, evaluation, dental cleaning, and treatment. In addition, materials and equipment necessary to perform a medically appropriate procedure are described. (*J Am Anim Hosp Assoc* 2013; 49:75–82. DOI 10.5326/JAAHA-MS-4013)

## Introduction

Veterinary medical dental care is an essential component of a preventive healthcare plan. Quality dental care is necessary to provide optimum health and quality of life. If left untreated, diseases of the oral cavity are painful and can contribute to other local or systemic diseases.<sup>1,2</sup> The purpose of this document is to provide guidelines for the practice of companion animal dentistry. A list of definitions to enhance the understanding of this article is provided in **Table 1**.

The dental health care team is obligated to practice within the scope of their respective education, training, and experience. It is imperative that the dental health care team remains current with regard to oral care, operative procedures, materials, equipment, and products. The team members must attain appropriate continuing education through courses such as those offered by the American Animal Hospital Association, the American Veterinary Medical Association, the annual Veterinary Dental Forum, industry and private facilities; by reading the *Journal of Veterinary Dentistry*; and by reading other appropriate journals and medical texts.<sup>3–7</sup>

## Facility Requirements

Dental procedures result in aerosolized bacteria and particulate matter. Using a dedicated space is recommended for non-sterile dental procedures. The dedicated dental space must be separate from the sterile surgical suite and needs to be placed in a low-traffic area. New practices and those planning on remodeling should incorporate a separate dental suite into the blueprint.

Appropriate ventilation and anesthetic scavenging systems must also be used. Low-heat, high-intensity lighting, and equipment for magnifying the target area are required to adequately and safely visualize the oral cavity and its structures. The operating table must allow for drainage and be constructed of impervious, cleanable material.

## Materials, Instruments, and Equipment

As with dental techniques, it is important to keep the dental materials up-to-date and veterinarians must be aware of what

From the Animal Dental Clinic, San Carlos, CA (S.H.); All Pets Dental Clinic, Weston, FL (J.B.); Veterinary Dental Center, River Heights Veterinary Hospital, Oswego, IL (S.J.); Pet Crossing Animal Hospital & Dental Clinic, Bloomington, MN (K.K.); California Veterinary Dental Specialties, San Diego, CA (B.N.); and Tampa Bay Veterinary Dentistry, Largo, FL (J.P.).

Correspondence: [Toothvet@sbcglobal.net](mailto:Toothvet@sbcglobal.net) (S.H.)

\*This document is intended as a guideline only. Evidence-based support for specific recommendations has been cited whenever possible and appropriate. Other recommendations are based on practical clinical experience and a consensus of expert opinion. Further research is needed to document some of these recommendations. Because each case is different, veterinarians must base their decisions and actions on the best available scientific evidence, in conjunction with their own expertise, knowledge, and experience. These guidelines are supported by generous educational grants from Hill's Pet Nutrition, Merial, Ltd., Virbac Animal Health, and PDx BioTech, and are endorsed by the American Veterinary Dental College.

**TABLE 1****Definitions that Pertain to Dental Guidelines\***

Term	Definition
Dental chart	A written and graphical representation of the mouth, with adequate space to indicate pathology and procedures (see Table 5 for included items)
Dental prophylaxis	A procedure performed on a healthy mouth that includes oral hygiene care, a complete oral examination, and techniques to prevent disease and to remove plaque and calculus from the teeth above and beneath the gum line before periodontitis has developed
Dentistry	The evaluation, diagnosis, prevention, and/or treatment of abnormalities in the oral cavity, maxillofacial area, and/or associated structures. Nonsurgical, surgical, or related procedures may be included
Endodontics	The treatment and therapy of diseases of the pulp canal system
Exodontia (extraction)	A surgical procedure performed to remove a tooth
Gingivitis	Inflammation of the gingiva without loss of the supporting structure(s) shown with X-ray
Oral surgery	The surgical invasion and manipulation of hard and soft tissue to improve/restore oral health and comfort
Orthodontics	The evaluation and treatment of malpositioned teeth for the purposes of improving occlusion and patient comfort and enhancing the quality of life
Periodontal disease	A disease process that begins with gingivitis and progresses to periodontitis when left untreated
Periodontitis	A destructive process involving the loss of supportive structures of the teeth, including the periodontium, gingiva, periodontal ligament, cementum, and/or alveolar bone
Periodontal surgery	The surgical treatment of periodontal disease. This is indicated for patients with pockets > 5 mm, class II or III furcation exposure, or inaccessible areas
Periodontal therapy	Treatment of tooth-supporting structures where periodontal disease exists. This involves the nonsurgical removal of plaque, calculus, and debris in pockets; and the local application of antimicrobials
Periodontium	The supporting structures of the teeth, including the periodontal ligament, gingiva, cementum, and alveolar and supporting bone
Pocket	A pathologic space between supporting structures and the tooth, extending apically from the normal site of the gingival epithelial attachment

\*Some of these definitions were derived from descriptions in Holmstrom *et al.* (2004).<sup>3</sup>

materials are considered appropriate for the treatment of dental conditions. Commonly used materials can be found by consulting a dental text and attending continuing education programs presented by a dental specialist.

Instruments and dental equipment require routine and frequent maintenance. Maintenance information can be found in some dental texts and through the manufacturer. Instruments must be sharp and properly stored, and instruments in poor condition need to be replaced. A written protocol needs to be established and followed for equipment and instrument care.

As with human dentistry, instruments that enter the oral cavity should be sterilized. Packets organized by dental procedure (e.g., examination, extraction, periodontal surgery) should be prepared and sterilized before use.

Recommended materials, instruments, and equipment for performing dental procedures are listed in **Tables 2** and **3**. Consult the reference list associated with these guidelines for recommendations and information on ordering equipment.<sup>3-7</sup>

## Operator Protection

Pathogens and debris such as calculus, tooth fragments, and prophylaxis paste are aerosolized during dental procedures. Irrigating the oral cavity with a 0.12% chlorhexidine solution before dental scaling decreases bacterial aerosolization.<sup>8</sup>

The safety of the operator must be ensured during dental procedures by using radiographic, oral, respiratory, skin, eye, and ear protective devices (**Table 4**). Ergonomic considerations include proper seating, fatigue mats for standing, and proper positioning of both the patient and materials to minimize immediate and chronic operator injuries. Provide the operator with instruction on proper instrument handling techniques.

## Patient Assessment

### History and Physical Examination

The history must include prior home dental hygiene delivered by the client; diet; access to treats and chews; chewing habits; current and previous dental care and procedures; prior and current diseases, including any behavioral issues and allergies; and medications or supplements currently administered. Perform a physical examination of all body systems based on the species, age, health status, and temperament of the animal. If the patient is presented for a complaint not related to dentistry, give due consideration to the primary complaint, performing the diagnostic tests and treatments indicated. Establish priorities if multiple procedures are indicated.

### Assessment by Life Stage

Focus on age-related dental conditions and common abnormalities in the dog and cat. From birth to 9 mo of age, evaluate the patient

**TABLE 2**

**Materials Needed for the Practice of Veterinary Dentistry\***

**Necessary materials**

- Antiseptic rinse
- Prophy paste/pumice
- Prophy angle and cups
- Hemostatic agents
- Sealant
- Needles and syringes
- Intraoral digital system or radiographic film
- Measures to prevent hypothermia (e.g., conductive blanket, hot air blanket, circulating water blanket, towels, blankets)
- Gauze and sponges
- Antimicrobial agent for local application
- Suture material (4-0 and smaller)
- Bone augmentation material
- Local anesthetic drugs

**Necessary equipment**

- Equipment to expose and process intraoral digital radiograph system or intraoral films
- Suction
- A high- and low-speed delivery system for air and water
- Fiber optic light source
- Equipment for sterilizing instruments
- Low- and high-speed hand pieces (minimum two of each)
- Various sizes of round/diamond and cross cut fissure burrs
- Powered scaler with tips for gross and subgingival scaling (ultrasonic, subsonic, or piezoelectric)
- Head or eye loupes for magnification

\*Please note that disposable items are for single use only.

for problems related to the deciduous teeth, missing or extra teeth, swellings, juvenile diseases (such as feline juvenile onset periodontitis), occlusion, and oral development. From 5 mo to 2 yr of age, evaluate the patient for problems related to developmental anomalies, permanent dentition, and the accumulation of plaque and calculus. Periodontal diseases may begin during that time period, especially in cats and small-breed dogs. The onset and severity of periodontal diseases varies widely depending on breed,

**TABLE 3**

**Instruments to Include in the Dental Surgical Pack\***

- Scalers
- Curettes
- Probes/explorer
- Sharpening materials
- Scalpel
- Extraction equipment (e.g., periosteal elevators, luxating elevators, periodontal elevators, extraction forceps, root tip picks, root tip forceps)
- Thumb forceps
- Hemostats
- Iris, LaGrange, Mayo, or Metzenbaum scissors
- Needle holders
- Mouth mirror
- Retraction aid (e.g., University of Minnesota retractor)

\*Instruments must be sterilized by accepted techniques prior to each use. Hand instruments must be properly sharpened and cared for.

**TABLE 4**

**Minimum Protective Devices to be used During Dental Procedures**

- Cap or hair bonnet
- Mask
- Goggles, surgical spectacles, or face shield
- Smock
- Gloves
- Earplugs
- Dosimeter
- Protection from radiation (e.g., lead shield)

diet, and home dental care. In a small-breed dog without home dental care, periodontal diseases can start as early as 9 mo of age. In a large-breed dog, periodontal diseases may not start until later. Many small-breed dogs have periodontal diseases by 3 yr of age.<sup>9-12</sup> Beyond 2 yr of age, evaluate the progression of periodontal diseases, damage to tooth structures, occurrence of oral masses, and the existence and adequacy of preventive home dental care. As the animal ages, continue to evaluate the patient for progressive periodontal diseases, oral tumors, and other aspects of dental pathology.<sup>13</sup>

**Oral/Dental Examination in the Conscious Patient**

Record all findings in the medical record (Table 5). Evaluate the head and oral cavity both visually and by palpation. Changes in body weight, eating habits, or other behaviors can indicate dental disease. Specific abnormal signs to look for may include pain; halitosis; drooling; dysphagia; asymmetry; tooth resorption; discolored, fractured, mobile, missing, or extra teeth; inflammation and bleeding; loss of gingiva and bone; and changes in the range of motion or pain in the temporomandibular joint. In addition, the practitioner should assess the patient's occlusion to ensure it is normal, or at least atraumatic. Evaluate the patient's eyes, lymph nodes, nose, lips, teeth, mucous membranes, gingiva, vestibule (i.e., the area between the gum tissue and cheeks), palatal and lingual surfaces of the mouth, dorsal and ventral aspects of the tongue, tonsils, and salivary glands and ducts. Note all abnormalities such as oral tumors, ulcers, or wounds. A diagnostic test strip for the measurement of dissolved thiol levels can be used as an exam room indicator of gingival health and periodontal status.<sup>14</sup>

The oral examination performed on a conscious patient allows the practitioner to design a preliminary diagnostic plan. Take into consideration potential patient pain. Do not offend the patient by probing unnecessarily when such manipulations can be better achieved under anesthesia. Also, realize in many instances that the examiner will underestimate the conditions present because it is impossible to visualize all oral structures



**TABLE 5****Items to Include in the Dental Chart and/or Medical Record**

- Signalment
- Physical examination, medical, and dental history findings
- Oral examination findings
- Anesthesia and surgery monitoring log and surgical findings
- Any dental, oral, or other disease(s) currently present in the animal
- Abnormal probing depths (described for each affected tooth)
- Dentition chart with specific abnormalities noted, such as discoloration; worn areas; missing, malpositioned, or fractured teeth; supernumerary, tooth resorption; and soft-tissue masses
- Current and future treatment plan, addressing all abnormalities found. This includes information regarding initial decisions, decision-making algorithm, and changes based on subsequent findings
- Recommendations for home dental care
- Any recommendations declined by the client
- Prognosis

when the patient is awake. It is only when the patient has been anesthetized that a complete and thorough oral evaluation can be accomplished successfully. The complete examination includes a tooth-by-tooth visual examination, probing, and radiographic examination. Only then can a precise treatment plan and fees for proposed services be tabulated and discussed with the pet owner(s).

## Making Recommendations and Client Education

Discuss the findings of the initial examination and additional diagnostic and/or therapeutic plans with the client. Those plans will vary depending on the patient; the initial findings; the client's ability to proceed with the recommendations; as well as the client's ability to provide necessary, lifelong plaque prevention.

When either an anesthetic examination or procedure is not planned in a healthy patient, discuss preventive healthcare, oral health, and home oral hygiene. Options include brushing and the use of dentifrices, oral rinses, gels and sprays, water additives, and dental diets and chews. Discourage any dental chew or device that does not bend or break easily (e.g., bones, cow/horse hooves, antlers, hard nylon products). The Veterinary Oral Health Council lists products that meet its preset standard for the retardation of plaque and calculus accumulation.<sup>15</sup> Illustrate to the owner how to perform oral hygiene, such as brushing, wiping teeth, application of teeth-coating materials, and the use of oral rinses and gels. Allow the client to practice so they will be able to perform the agreed-upon procedure(s) at home.

All home oral hygiene options, from diet to the gold standard of brushing, along with any of their potential limitations need to be discussed with the client. It is essential that the oral health medical plan is patient-individualized to attain the greatest level of client

compliance. For example, "dental" diets and chews can be used until the client is comfortable either brushing or applying an antiplaque gel, rinse, or spray with a wipe. The gold standard is brushing the pet's teeth using a brush with soft bristles either once or twice daily. If the client is either unable or unwilling to persevere with brushing, use any of the other oral hygiene options that the patient will tolerate.

Explain the two-part process involved in a diagnostic dental cleaning and patient evaluation to the client. It is critical that he/she understand the hospital protocol to minimize miscommunication and frustration. The procedure involves both an awake component and an anesthetized component for a complete evaluation. It is not until the oral radiographs have been evaluated that a full treatment plan including costs of the anticipated procedure(s) can be successfully made with any degree of accuracy.

Evaluation of a patient for dental disease involves the awake procedure as the first step. This is where an initial assessment is made. Although many problems may be seen at this point of the evaluation, a thorough diagnosis and treatment plan cannot be determined until charting, tooth-by-tooth examination of the anesthetized patient, and dental radiographs have been taken and evaluated. Studies have demonstrated that much of the pathology in a patient's oral cavity cannot be appreciated until dental radiographs are taken and assessed; therefore, have protocols in place within the practice to give clients ample time to make an informed decision on how they want to proceed with the proposed treatment plan.<sup>16</sup>

Some hospitals may want to do the awake examination and the anesthetic component (charting, cleaning, and dental radiographs) as the first procedure. They can then stage the treatment plan as a second procedure. This will give the hospital staff adequate time to explain to the client the treatment plan, including giving educational information on the diagnosis, reviewing radiographic findings, and going over costs. Other hospitals may want to perform the treatment plan during the first anesthetic event so everything is done at that procedure. Whichever way the hospital chooses, there must be a client communication plan in place so the client is involved and feels comfortable going forward with the proposed treatment plan.

Perform the anesthetized portion of the dental evaluation of charting, cleaning, and radiographs when abnormalities are seen on the awake exam (such plaque or tartar at the free gingival surface of the maxillary canines or fourth premolars) or at least on an annual basis starting at 1 yr of age for cats and small- to medium-breed dogs and at 2 yr of age for large-breed dogs. Details on the recommended frequency of examinations are discussed under Progress or Follow-Up Evaluation (below).

## Planning the Dental Cleaning and Patient Evaluation

Use well-monitored, inhalation anesthesia with cuffed intubation when performing dental cleanings. Such techniques increase safety, reduce stress, decrease the chances of adverse sequelae (e.g., inhalation pneumonia), and are essential for thorough and efficient evaluation and treatment of the patient. Attempting to perform procedures on an awake patient that is struggling, under sedation, or injectable anesthesia reduces the ability to make an accurate diagnosis, does not allow adequate treatment, and increases stress and risks to the patient.

### Prior to Anesthesia

Preoperative evaluation includes a preanesthetic physical examination. It is crucial to follow the most up-to-date recommendations for preoperative laboratory testing based on the patient's life stage and any existing disease. Preoperative care includes IV catheterization to facilitate administration of IV fluid therapy, preemptive pain management, and antibiotics (when indicated). Review the most up-to-date guidelines on anesthesia, antimicrobial use, fluid therapy, feline life stage, canine life stage, preventive healthcare, pain management, and referral for specific recommendations.<sup>17–25</sup>

### Anesthesia

General anesthesia with intubation is necessary to properly assess and treat the companion animal dental patient. It is essential that aspiration of water and debris by the patient is prevented through endotracheal intubation. Cleaning a companion animal's teeth without general anesthesia is considered unacceptable and below the standard of care. Techniques such as necessary immobilization without discomfort, periodontal probing, intraoral radiology, and the removal of plaque and tartar above and below the gum line that ensure patient health and safety cannot be achieved without general anesthesia.<sup>26</sup>

During anesthesia, one trained person is dedicated to continuously monitoring and recording vital parameters, such as body temperature, heart rate and rhythm, respiration, oxygen saturation via pulse oximetry, systemic blood pressure, and end-tidal CO<sub>2</sub> levels *q* 5 min (or more frequently if sudden changes are noted).<sup>27,28</sup> IV fluid therapy is essential for circulatory maintenance. Customize the type and rate of fluids administered according to the patient's needs.<sup>29,30</sup>

Prevention of hypothermia with warming devices is essential because the patient may become wet, and dental procedures can be lengthy.<sup>31,32</sup> Additionally, suction and packing the caudal oral cavity with gauze can prevent aspiration and decrease hypothermia. If packing materials are used, steps must be taken to ensure there is no chance of the material being left behind following

extubation. Regardless of whether packing is used, the last step prior to extubation is an examination of the caudal oral cavity to make certain no foreign material is left behind. Proper positioning of the patient by placing them in lateral recumbency can also help prevent aspiration. Provide safe immobilization of the head.

If oral surgery is planned, the institution of an intraoral local anesthetic is warranted in conjunction with the general anesthesia. This decreases the amount of general anesthetic needed and reduces the amount of systemic pain medication required post-operatively.<sup>1,27,33</sup> Local anesthetic blocks can last up to 8 hr, and they decrease hypotension and hypoventilation caused with inhalant anesthetics by reducing the amount of gas needed to maintain a safe anesthetic plane.<sup>3,6,34,35</sup>

## Dental Procedures

The terms *prophy*, *prophylaxis*, and *dental* are often misused in veterinary medicine. A professional dental cleaning is performed on a patient with plaque and calculus adhered to some of the teeth, but otherwise has an essentially healthy mouth or mild gingivitis only. The intent of dental cleaning is to prevent periodontitis. Patients with existing disease undergo periodontal therapy in addition to professional dental cleaning. Dental procedures must be performed by a licensed veterinarian, a credentialed technician, or a trained veterinary assistant under the supervision of a veterinarian in accordance with state or provincial practice acts. Practice acts vary from jurisdiction to jurisdiction, and the veterinarian must be familiar with those laws. Surgical extractions are to be performed only by trained, licensed veterinarians. All extractions need to have postextraction, intraoral radiographs. All dental procedures need to be described properly (Table 1), and a consistent method should be used to record findings in the medical record (Table 5).

Positioning and safety of the patient is important. Manually stabilize the head and neck when forces are being applied in the mouth. Avoid using mouth gags because they can cause myalgia, neuralgia, and/or trauma to the temporomandibular joint. If a mouth gag is necessary, do not fully open the mouth or overextend the temporomandibular joint. Never use spring-loaded mouth gags. Do not overinflate the endotracheal tube. Always disconnect the endotracheal tube when repositioning the patient to prevent trauma to the trachea.

### Essential Steps for Professional Dental Cleaning

The essential steps for a professional dental cleaning and periodontal therapy are described in the following list:

1. Perform an oral evaluation, as described above, for the conscious patient.

2. Radiograph the entire mouth, using either intraoral or digital radiographic systems. Radiographs are necessary for accurate evaluation and diagnosis. In one published report, intraoral radiographs revealed clinically important pathology in 27.8% of dogs and 41.7% of cats when no abnormal findings were noted on the initial examination.<sup>16</sup> In patients with abnormal findings, radiography revealed additional pathology in 50% of dogs and 53.9% of cats.<sup>16</sup> Standard views of the skull are inadequate when evaluating dental pathology. If full mouth films are not taken, the client must be informed that they were not done.
3. Scale the teeth supra- and, most importantly, subgingivally using either a hand scaler or appropriate powered device followed by a hand instrument (i.e., scaler, curette). Do not use a rotary scaler, which excessively roughens the tooth enamel.<sup>36</sup>
4. Polish the teeth using a low-speed hand piece running at no more than 300 revolutions/min with prophylactic paste that is measured and loaded on a disposable prophylactic cup for each patient (to avoid cross-contamination).
5. Perform subgingival irrigation to remove debris and polishing paste and to inspect the crown and subgingival areas.
6. Apply antiplaque substances, such as sealants.
7. Provide instructions to the owner regarding home oral hygiene.

### Additional Steps for Periodontal Therapy and Other Conditions

8. Evaluate the patient for abnormal periodontal pocket depths using a periodontal probe. The depth that is considered abnormal varies depending on the tooth and size of the dog or cat.<sup>3,4,6,37</sup> In medium-sized dogs, the probing depth should not be > 2 mm, and in the mid-sized cats, the depth should not be > 1 mm.
9. Perform periodontal therapy (Table 1) based on radiographic findings and probing.<sup>38–40</sup>
10. Administer perioperative antibiotics when indicated, either parenterally or locally.<sup>41,42</sup>
11. Perform periodontal surgery to remove deep debris, eliminate pockets, and/or extract teeth. When either pockets or gingival recession is > 50% of the root support, extraction or periodontal surgery is indicated and should be performed by trained veterinarians or referred to a specialist.
12. Biopsy all abnormal masses that are visualized grossly or noted on radiographs. Submit all samples for histopathology to be analyzed by a pathologist qualified in oral tissues analysis.<sup>43</sup>

13. Take postoperative radiographs to evaluate the treatment applied. This is especially important in extraction cases.
14. Examine and rinse the oral cavity. Remove any packing or foreign debris.
15. Recommend referral to a specialist when the primary veterinary practitioner does not have the skills, knowledge, equipment, or facilities to perform a specific procedure or treatment.

## Postoperative Management

Maintain an open airway via intubation until the animal is either swallowing or in sternal recumbency. Maintain body temperature and continue IV fluid support as needed. Continuously monitor and record vital signs until the patient is awake. Assess and record pain scores throughout the recovery period, continuing pain management while the pet is in the hospital and upon discharge.<sup>34,44</sup>

## Client Education and Follow-up Postoperative Communication

Client communication is fundamental to the maintenance of oral health. At the time of discharge, discuss all operative procedures and existing/potential complications (e.g., sedation, vocalization, bleeding, coughing, dehiscence, infection, neurologic signs, halitosis, vomiting, diarrhea, anorexia, signs of pain). Discuss immediate postoperative home oral hygiene, including medications and their side effects. Provide antibiotics and medication for inflammation and pain as indicated.<sup>41,42</sup> Discuss any change in diet that might be necessary, such as a change to either soft or pre-moistened food or to a prescription dental diet. Also indicate the duration of those changes. Provide individualized oral and written instructions at the time of discharge. Establish an appointment for a follow-up examination and further discussion.

## Home Oral Hygiene

Home oral hygiene is vital for disease control. Telephone the client the day after the procedure to inquire about the pet's condition, to determine the client's ability to implement the medication and home oral hygiene plan, to answer questions, and address any concerns the client might have. The home oral hygiene plan includes the frequency, duration, and method of rinsing and brushing; applying sealants; and the use of dental diets and dental chews.<sup>45</sup> The Veterinary Oral Health Council has a list of products that are reportedly effective in retarding the accumulation of dental plaque and/or calculus.<sup>46</sup> Some of the details regarding the home oral hygiene plan might best be left for discussion with the client at the first postoperative follow-up evaluation.

## Progress or Follow-up Evaluation

With each follow-up examination and telephone communication, repeat the home dental care instructions and recommendations to the client. Set the number and timing of regular follow-up visits based on the disease severity. Although few studies have been performed in dogs and cats, extrapolation from the human literature and guidelines about aging in dogs and cats leads to the following recommendations:<sup>14</sup>

- Dental health care needs to be part of the preventive healthcare examination discussion and should begin at the first appointment at which the patient is seen and continue routinely throughout subsequent exams.
- Examinations *q* 6 mo can help ensure optimal home oral hygiene. At a minimum, evaluate animals with a healthy mouth at least *q* 12 mo.
- Evaluate pets with gingivitis at least *q* 6 mo.
- Evaluate pets with periodontitis at least *q* 3–6 mo.
- Advanced periodontal disease requires examinations *q* 1 mo until the disease is controlled.

Evaluate disease status, such as periodontal disease, on the conscious patient with products that allow an assessment of periodontal health without placing the patient under anesthesia.<sup>14</sup> During subsequent examinations, evaluate client compliance, revise the treatment plan as needed, and redefine the prognosis.

## Nutrition

Nutrition plays an important role in oral health; therefore, it is important for the healthcare team to have an understanding of the impact of nutrition on their patients. A properly balanced diet is essential for good general health, including health of oral tissues. For good oral health, it is the form of the diet, not the nutritional content, that is critical for good oral health. A diet that provides mechanical cleansing of the teeth is an excellent way of retarding the accumulation of dental plaque and calculus. Dental diets and chews can be very effective if the owner is unable to brush the teeth. Dental diets work either by “brushing” the crowns of the teeth as the animal chews or by coating an anticalculus agent on the surface of the teeth. Nutrition becomes even more critical in dental health when the client is unable to provide home oral hygiene by brushing.<sup>47</sup> During subsequent examinations, evaluate client compliance, revise the treatment plan as needed, and redefine the prognosis.

## Conclusion

Pets can live more comfortable lives if oral health care is managed and maintained. All members of the veterinary team must strive to increase the quality of dental care delivered. Clients must be given

options for the optimal care and treatment available for their pets. Dentistry is becoming more specialized, and referral to a veterinary dental specialist or a general practitioner with advanced training and proper equipment is recommended if the necessary expertise and/or equipment are unavailable at the primary veterinarian’s office. ■

## REFERENCES

1. Beckman BW. Pathophysiology and management of surgical and chronic oral pain in dogs and cats. *J Vet Dent* 2006;23(1):50–60.
2. Carpenter RE, Manfra M, Maretta S. Dental patients. In: Tranquilli WT, Grimm KA, Thurmon J, eds. *Lumb and Jones’ veterinary anesthesia and analgesia*. 4th ed. Philadelphia (PA): Wiley-Blackwell; 2007: 993–5.
3. Holmstrom SE, Frost-Fitch P, Eisner ER. *Veterinary dental techniques for the small animal practitioner*. 3rd ed. Philadelphia (PA): WB Saunders; 2004.
4. Holmstrom SE. *Veterinary dentistry: a team approach*. 2nd ed. St. Louis (MO): Elsevier; 2012.
5. Wiggs RB, Lobprise HB. *Veterinary dentistry: principles and practice*. Philadelphia (PA): Lippincott-Raven; 1997.
6. Bellows J. *Small animal dental equipment, materials and techniques*. 1st ed. Ames (IA): Blackwell; 2004.
7. Mulligan T, Aller MS, Williams CA. *Atlas of canine and feline dental radiography*. Trenton (NJ): Veterinary Learning Systems; 1998.
8. Logothetis DD, Martinez-Welles JM. Reducing bacterial aerosol contamination with a chlorhexidine gluconate pre-rinse. *J Am Dent Assoc* 1995;126(12):1634–9.
9. Grove TK. Periodontal disease. In: Harvey C, ed. *Veterinary dentistry*. Philadelphia (PA): WB Saunders; 1985:59–78.
10. Harvey CE, Emily PP. *Small animal dentistry*. St. Louis (MO): Mosby Year Book; 1993:89–144.
11. Hennes PR, Harvey CE. Natural development of periodontal disease in the dog: a review of clinical, anatomical and histological features. *J Vet Dent* 1992;9(3):13–9.
12. Harvey CE, Shofer FS, Laster L. Association of age and body weight with periodontal disease in North American dogs. *J Vet Dent* 1994;11(3):94–105.
13. Niemiec BA. Systemic manifestations of periodontal disease. In: Niemiec BA, ed. *Veterinary periodontology*. Ames (IA): Wiley-Blackwell; 2012:81–90.
14. Manfra M, Marretta S, Leesman M, Burgess-Cassler A, et al. Pilot evaluation of a novel test strip for the assessment of dissolved thiol levels, as an indicator of canine gingival health and periodontal status. *Can Vet J* 2012;1260.
15. Veterinary Oral Health Council. Available at: [www.vohc.com](http://www.vohc.com). Accessed January 24, 2013.
16. Verstraete FJ, Kass PH, Terpak CH. Diagnostic value of full-mouth radiography in cats. *Am J Vet Res* 1998;59(6):692–5.
17. Epstein M, Kuehn N, Landsberg G, et al. AAHA senior care guidelines for dogs and cats. *J Am Anim Hosp Assoc* 2005;41(2): 81–91. Available at: [www.aahanet.org/Library/Guidelines.aspx](http://www.aahanet.org/Library/Guidelines.aspx). Accessed January 24, 2013.
18. Bednarski R, Grimm K, Harvey R, et al. AAHA anesthesia guidelines for dogs and cats. *J Am Anim Hosp Assoc* 2011;47(6):377–85. Available at: [www.aahanet.org/Library/Guidelines.aspx](http://www.aahanet.org/Library/Guidelines.aspx). Accessed January 24, 2013.

19. AAHA/AAFP Basic guidelines of judicious therapeutic use of antimicrobials. Available at: [www.aahanet.org/Library/Guidelines.aspx](http://www.aahanet.org/Library/Guidelines.aspx). Accessed January 24, 2013.
20. Bartges J, Boynton B, Vogt AH, et al. AAHA canine life stages guidelines. *J Am Anim Hosp Assoc* 2012;48(1):1–11. Available at: [www.aahanet.org/Library/Guidelines.aspx](http://www.aahanet.org/Library/Guidelines.aspx). Accessed January 24, 2013.
21. Hoyumpa Vogt A, Rodan I, Brown M, et al. AAFP-AAHA feline life stages guidelines. *J Feline Med 378 Surg* 2010;12(1):43–54. Available at: [www.aahanet.org/Library/Guidelines.aspx](http://www.aahanet.org/Library/Guidelines.aspx). Accessed January 24, 2013.
22. AAHA/AAFP Fluid Therapy Guidelines. 2013. In press.
23. Hellyer P, Rodan I, Brunt J, et al. AAHA/AAFP pain management guidelines for dogs and cats. *J Am Anim Hosp Assoc* 2007;43(5):235–48. Available at: [www.aahanet.org/Library/Guidelines.aspx](http://www.aahanet.org/Library/Guidelines.aspx). Accessed January 24, 2013.
24. Development of new canine and feline preventive healthcare guidelines designed to improve pet health. American Animal Hospital Association-American Veterinary Medical Association Preventive Healthcare Guidelines Task Force. *J Am Anim Hosp Assoc* 2011 Sep-Oct;47(5):306–11.
25. AAHA referral guidelines. Available at: [www.aahanet.org/Library/Guidelines.aspx](http://www.aahanet.org/Library/Guidelines.aspx). Accessed January 24, 2013.
26. American Veterinary Dental College. American Veterinary Dental College position statement: companion animal dental scaling without anesthesia. Available at: [http://avdc.org/Dental\\_Scaling\\_Without\\_Anesthesia.pdf](http://avdc.org/Dental_Scaling_Without_Anesthesia.pdf). Accessed January 24, 2013.
27. Pascoe P. Anesthesia and pain management. In: Verstraete F, Lommer M, eds. *Oral and maxillofacial surgery in dogs and cats*. WB Saunders; 2012:26–7.
28. Stepaniuk K, Brock N. Anesthesia monitoring in the dental and oral surgery patient. *J Vet Dent* 2008;25(2):143–9.
29. Thurmon JC, et al. Acid-base balance and fluid therapy. In: *Essentials of small animal anesthesia and analgesia*. Philadelphia: Lippincott, Williams & Wilkins; 1999:339–74.
30. Seeler D. Fluid, electrolyte, and blood component therapy. In: *Veterinary Anesthesia and Analgesia*. Blackwell Publishing; 2007:185–96.
31. Hale FA, Anthony JM. Prevention of hypothermia in cats during routine oral hygiene procedures. *Can Vet J* 1997;38(5):297–9.
32. Stepaniuk K, Brock N. Hypothermia and thermoregulation during anesthesia for the dental and oral surgery patient. *J Vet Dent* 2008;25(4):279–83.
33. Chapman PJ, Ganendran A. Prolonged analgesia following preoperative bupivacaine neural blockade for oral surgery performed under general anesthesia. *J Oral Maxillofac Surg* 1987;45(3):233–5.
34. Tranquilli WJ, Grimm KA, Lamont LA. *Pain management for the small animal practitioner*. Jackson (WY): Teton New Media; 2000:13–30.
35. Lantz GC. Regional anesthesia for dentistry and oral surgery. *J Vet Dent* 2003;20(3):181–6.
36. Brine EJ, Marretta SM, Pijanowski GJ, et al. Comparison of the effects of four different power scalers on enamel tooth surface in the dog. *J Vet Dent* 2000;17(1):17–21.
37. Niemiec BA. *Veterinary periodontology*. Ames (IA): Wiley-Blackwell; 2012.
38. Beckman BW. Patient management for periodontal therapy. In: Niemiec BA, ed. *Veterinary periodontology*. Ames (IA): Wiley-Blackwell; 2012:305–12.
39. Niemiec BA. Advanced non-surgical therapy. In: Niemiec BA, ed. *Veterinary periodontology*. Ames (IA): Wiley-Blackwell; 2012:154–69.
40. Niemiec BA. The complete dental cleaning. In: Niemiec BA, ed. *Veterinary periodontology*. Ames (IA): Wiley-Blackwell; 2012:129–53.
41. Hennet P. Periodontal disease and oral microbiology. In: Crossley DA, Penman S, eds. *Manual of small animal dentistry*. 2nd ed. Shurdington (England): British Small Animal Veterinary Association; 1995:105–13.
42. Sarkiala E, Harvey C. Systemic antimicrobials in the treatment of periodontitis in dogs. *Semin Vet Med Surg (Small Anim)* 1993;8(3):197–203.
43. Huffman LJ. Oral examination. In: Niemiec BA, ed. *Small animal dental, oral and maxillofacial disease: a color handbook*. London: Manson; 2010:39–61.
44. Quality of Care. *Pain Management*. Lakewood (CO): American Animal Hospital Association Standards of Accreditation; 2003.
45. Niemiec BA. Home plaque control. In: Niemiec BA, ed. *Veterinary periodontology*. Ames (IA): Wiley-Blackwell; 2012:175–85.
46. Veterinary Oral Health Council. Available at: [www.vohc.org/accepted\\_products.htm](http://www.vohc.org/accepted_products.htm). Accessed January 24, 2013.
47. Jensen L, Logan E, Finney O, et al. Reduction in accumulation of plaque, stain, and calculus in dogs by dietary means. *J Vet Dent* 1995;12(4):161–3.

#### SUPPLEMENTARY REFERENCES

- Bellows J. *Feline Dentistry*. Ames (IA): Wiley; 2010
- Dupont GA, DeBowes LJ. *Atlas of dental radiography in dogs and cats*. St. Louis (MO): WB Saunders; 2009.

# Aging Horses by Their Teeth

Steven Jones  
Associate Professor -  
Animal Science

Dr. Nancy Jack  
Director, Dorothy E. King  
Equine Program  
Animal Science  
University of Arkansas

Dr. Patricia Evans  
Assistant Professor  
and Extension  
Equine Specialist  
Utah State University

Being able to pinpoint age within a fairly narrow range can be of use to owners of unregistered horses or horses whose age is unknown for any reason. Many health and nutrition management decisions are directly related to age and dental wear, making it even more important for all horse owners to have a general understanding of how a horse's mouth changes with age. From a historical perspective, up until recently when organized associations started keeping birth dates on registered horses, most professional horsemen took great pride in their ability to determine age by examining the teeth of any horse. Aging the horse by its teeth is not an exact science, but changes do occur

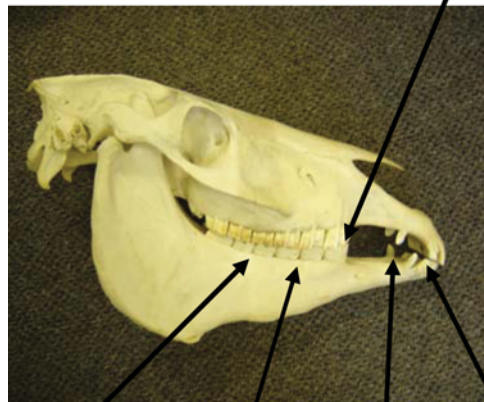
that can help determine approximate age. Anyone can learn the basics.

To use as a reference guide, Figures 1 and 2 indicate the names of the teeth.

Horses under 5 years of age go through some very typical dental changes. A good rule of thumb with foals is their milk teeth, or deciduous teeth, erupt, or come in, following a simple timetable of 8 days, 8 weeks and 8 months. Foals are born either without teeth or with four central incisors, two on the top and two on the bottom. If the central incisors are not present at birth, they usually erupt within 8 days. The intermediate

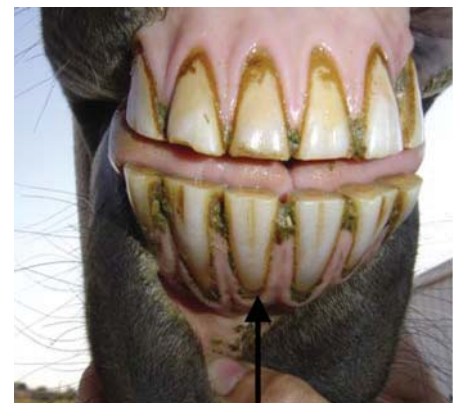
**Figure 1**

Wolf tooth does not appear in this picture, but it is considered the first premolar and would be found just in front of the first large premolar.



Molars – last three molars  
Premolars – first three large molars  
Canines  
Incisors

**Figure 2**



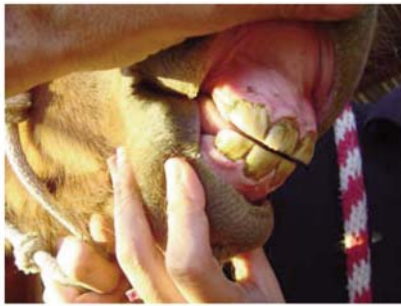Incisors

*Arkansas Is  
Our Campus*

Visit our web site at:  
<http://www.uaex.edu>

incisors erupt by 8 weeks (Figure 3) and the corner incisors by about 8 months. These are deciduous or temporary milk teeth that will be shed as the young horse ages. The deciduous teeth can be distinguished from permanent teeth because they are wider than they are tall and have shallow roots. Twelve premolars will also erupt, three on each side of the top and bottom jaws, within 2 weeks of age. However premolars are typically not used in aging horses as they are more difficult to view.

**Figure 3**



**A weanling with central and intermediate deciduous teeth in, but corner incisors have not erupted yet. This means it is between 8 weeks and 8 months of age.**

Other dental changes occur in yearly increments, and the young horse's mouth changes like a child's does as they shed their deciduous teeth. This systematic shedding of deciduous teeth is used to "age" horses until they have all of their permanent teeth at 5 years of age.

What follows is the pattern of deciduous tooth shedding. At 2½ years the horse's deciduous central incisors are pushed out of the way as the permanent centrals erupt from below (Figure 4). At 3 years the upper central and lower central incisors have grown out enough to meet and, therefore, begin to grind against one another. This is referred to as being "in wear." These wear patterns will be used later in the horse's life to help determine age. At 3½ years the intermediate incisors will be shed, and at 4 years of age they will be in wear (Figure 5). At 4½ years the corner incisors will be shed, and 6 months later they will be in wear. Male horses have four canine teeth (tushes) located between their corner incisor and the molars. See Table 1 for list of dental changes.

Mares will occasionally have canine teeth. These are usually not as developed, and all four may not be present. These teeth appear during the horse's fourth year. They should not be confused with wolf teeth, which are very shallowly rooted and found adjacent to the first premolar.

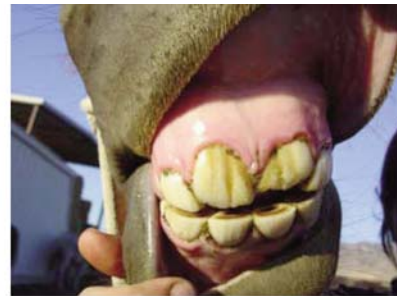Wolf teeth are commonly extracted as they may interfere with the bit. Canine teeth are not extracted under normal circumstances. Horses are considered to have a "full mouth" at 5, which means that all permanent teeth have erupted and are in wear.

**Table 1. The Average Times When Teeth Erupt**

Tooth	Eruption
<b>Deciduous:</b>	
1st incisor (or centrals)	birth or first week
2nd incisor (or intermediate)	4 to 6 weeks
3rd incisor (or corners)	6 to 9 months
1st premolar	
2nd premolar	birth or first 2 weeks for all
3rd premolar	premolars
<b>Permanent:</b>	
1st incisor (or centrals)	2½ years
2nd incisor (or intermediate)	3½ years
3rd incisor (or corners)	4½ years
Canine (or bridle)	4 to 5 years
1st premolar (or wolf tooth)	5 to 6 months
2nd premolar	2½ years
3rd premolar	3 years
4th premolar	4 years
1st molar	9 to 12 months
2nd molar	2 years
3rd molar	3½ to 4 years

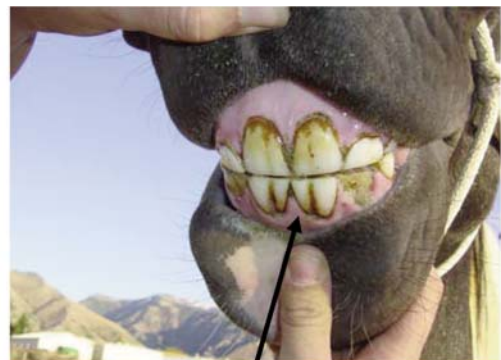Table from *Horses* by J. Warren Evans.

**Figure 4**



**2½ years old. Top central incisors are permanent but not in wear, but bottom centrals are still deciduous.**

**Figure 5**



**3½ years old. Centrals are permanent; intermediates are loose and ready to fall out.**

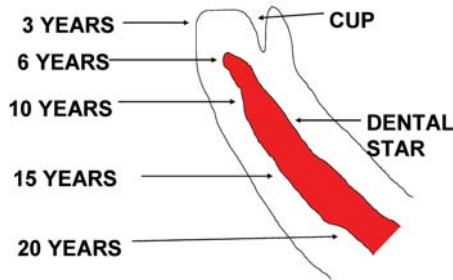
Once all permanent teeth are present, other indicators assist with determining age. On the grinding surface of the incisors, a cup is seen as an indented area with a dark center in the middle of each tooth. The cups disappear from the bottom central incisors at 6 years of age, the intermediates at 7 and the corners at 8. The top incisors lose the cups from central to corners at 9, 10 and 11 years of age, respectively. The term “smooth-mouthed horse” applies to a horse 12 years of age or older when all cups are gone and the grinding surface is smooth (Figures 6a and 6b).

Next to appear on the grinding surface of the incisors is a dental star or yellowish-colored spot. It appears more toward the front of the teeth (closer to the lips) than the cups (Figure 6a). At first this star is rectangular in appearance, but as the horse ages, it becomes more rounded and moves to the center of the

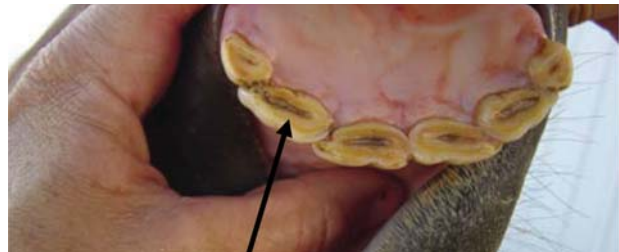tooth. The dental star will appear in the central incisors at 8 years of age, intermediates at 9 and corners at 10.

The shape of the grinding surface, amount of tooth seen below the gum line and angle of the teeth change with age. A horse under 9 years of age will have a rectangular grinding surface, a horse from 9 to mid-teens will have a more rounded grinding surface, while a horse in its later teens or older will have a triangular surface (Figures 7a and 7b). The younger horse will show a shorter tooth visible below the gum line, while a term used for the older horse is “long in the tooth” due to more visible tooth. When viewed from the side with lips parted, the young horse will exhibit a more vertical alignment to the incisors, while an older horse will have more of an angle with a more protruded appearance (Figures 8a and 8b.)

**Figure 6a**

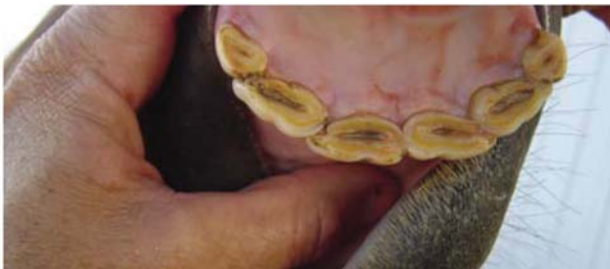

**Figure 6b**



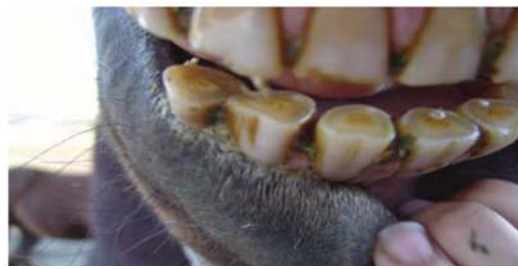Cups as seen in a young horse less than 6 years of age. All cups are still present.

**Figure 7a**



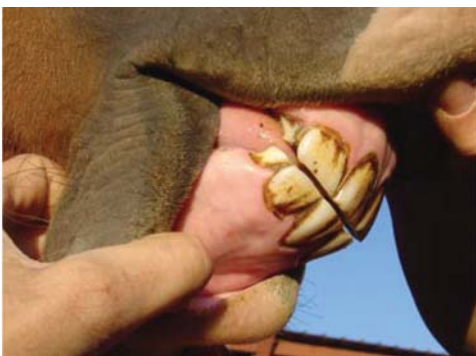Young horse's mouth with cups and rectangular table or grinding surface.

**Figure 7b**



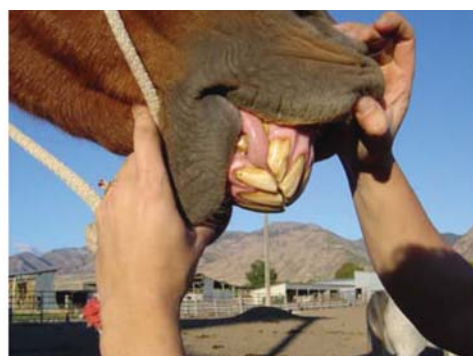Old horse's mouth with dental stars and triangular table.

**Figure 8a**



Young horse with a more vertical profile and less length of tooth visible.

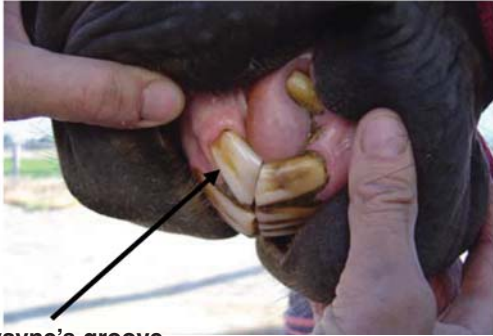**Figure 8b**



Older horse with a more angled profile and more length of tooth visible.



**Figure 9**

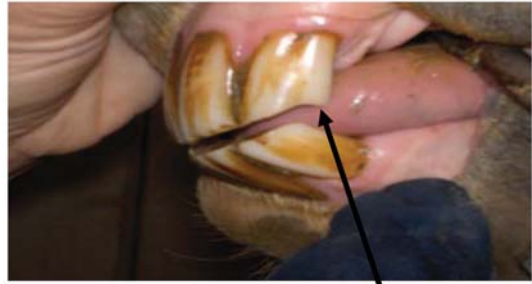

**Galvayne's groove**

A more subtle indicator that can assist with aging the horse over 10 years of age is the Galvayne's groove (Figure 9). This is a groove that appears near the gum line of the corner incisor. It begins at the center of the outer surface of the tooth in a 10-year-old. At 15 the groove extends halfway down the tooth, at 20 it extends the entire length of tooth, at 25 the upper half of the groove is gone so a groove appears only in the bottom half and at 30 the groove is completely gone.

Another subtle indicator on the same corner tooth is the 7- and 11-year hook. As the mouth changes shape, the rear of the top and bottom corner incisors may not meet, allowing for a hook to form on the top incisor (Figure 10). The first time this hook appears is during the seventh year, and it will disappear at

**Figure 10**



**This mare has hook at 11 years old due to lack of opposing surface at the back edge of the top molar.**

9 years of age. It will reappear at 11 years of age and may remain through the mid-teens.


These guidelines for aging by dental wear can vary depending on what the horse is eating and on vices. For example, horses that crib can wear down the top incisors, interfering with normal dental wear. While all horses do not follow the rules, these guidelines can be useful tools in evaluating a horse's age.

## References

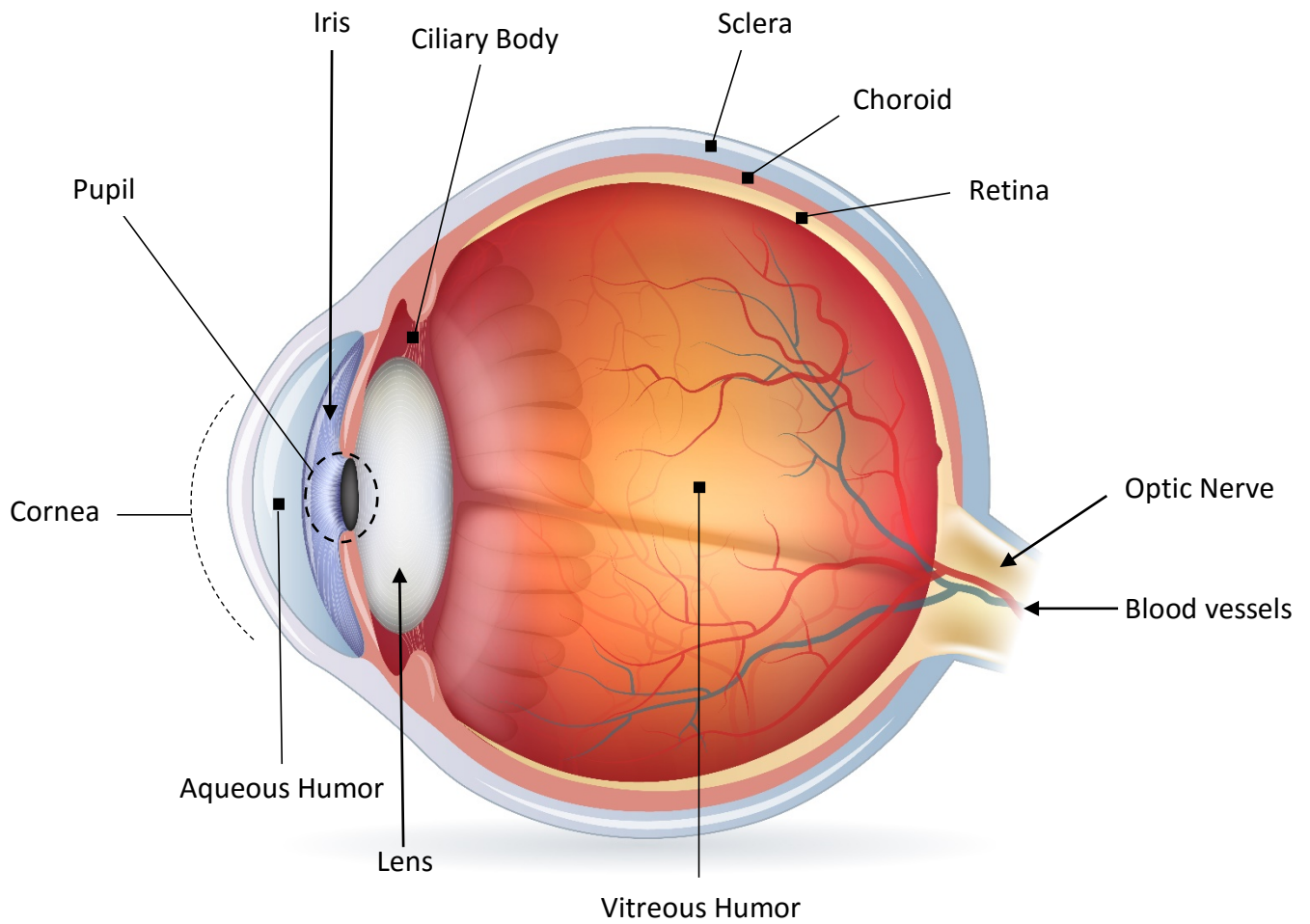
- Jeffrey, D. 1996. *Horse Dentistry, The Theory and Practice of Equine Dental Maintenance*. Norfolk, Nebraska: Norfolk Printing Company.
- Evans, J. W. 1981. *Horses*. San Francisco: W. H. Freeman and Company.



# Eye Dissection Laboratory



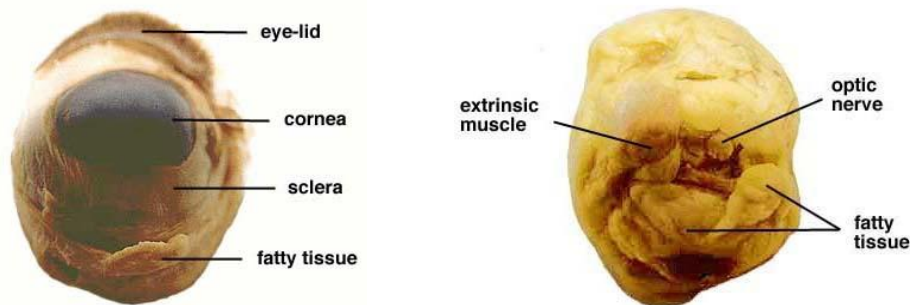
# Eye Anatomy



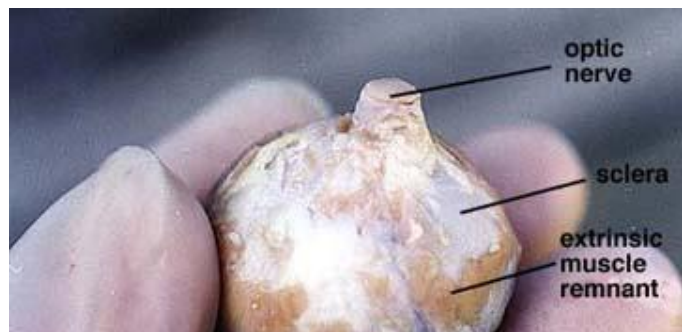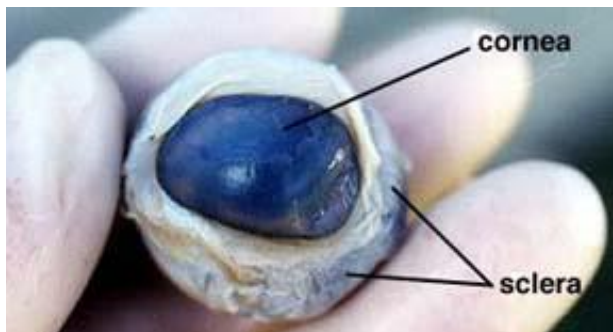# Sheep Eye Dissection Procedure

The anatomy of the eye can be better shown and understood by the actual dissection of an eye. The sheep eye closely resembles a human eye. Differences between the two eye types will be mentioned as the dissection is completed. Begin the dissection by gathering the equipment and supplies listed here.

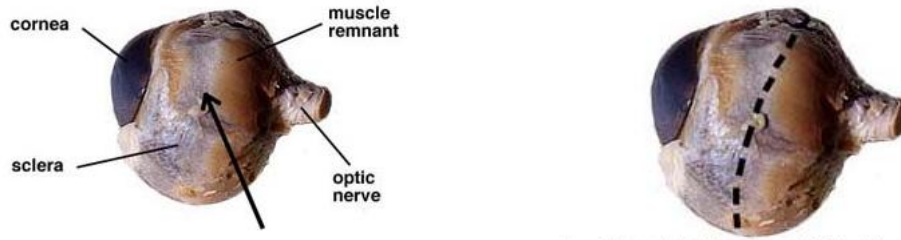
**Materials Needed:** (sheep eye, dissecting pan, gloves, scissors, scalpel, forceps, paper towels and a notebook and pencil for recording information about the eye as it is dissected.)



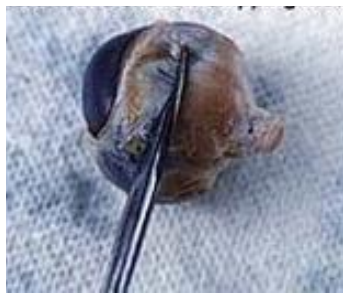**Step 1:** Examine the front of the eye and locate the eye-lid, cornea, sclera (white of the eye) and fatty tissue. Examine the back of the eye and find extrinsic muscle bundles, fatty tissue and the optic nerve. The four extrinsic muscles (humans have six) move the sheep eye while the fatty tissue cushions the eye. If the optic nerve is not visible use the probe to move the fatty tissue around until the nerve is exposed.



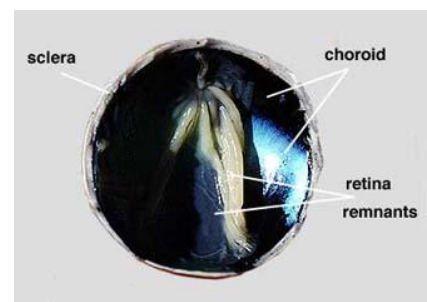
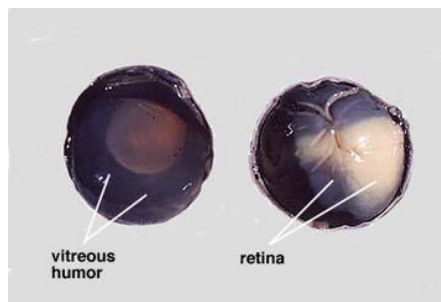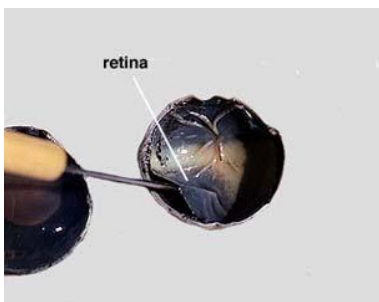
**Step 2:** Use your scissors to cut away the eye-lid (if necessary), muscle and fatty tissue from both the front and rear surfaces of the eye. Be careful **not** to remove the optic nerve! Cut along the surface of the sclera until all the tissue is removed and your specimen looks similar to the photographs you see here. The sclera is very tough so you do not need to worry about cutting into this layer of the eye. When you have finished removing the tissue surrounding the eye identify the sclera, cornea, optic nerve, and the remaining external muscle parts. The cloudy nature of the cornea is caused by the non-living tissue. It is transparent in the living state.



**Step 3:** Place your eye specimen in the dissection pan. Turn the specimen so the cornea is on the left and the optic nerve is on your right. Select a place to make an incision of the sclera midway between the cornea and optic nerve. Use the point of a very sharp razor blade to make a small cut through the sclera. Fluid should ooze out of the eyeball when you have cut deeply enough. You will be reminded of how tough the sclera is when you make this cut.



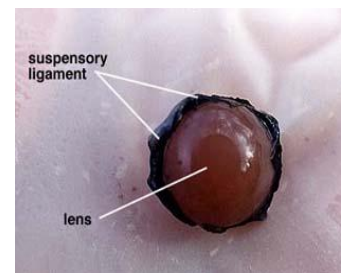
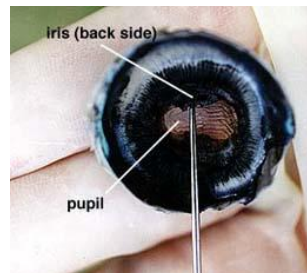
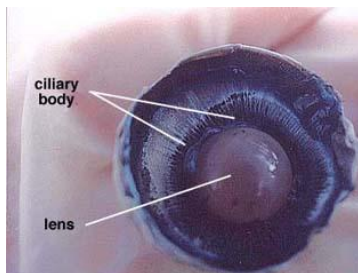
**Step 4:** Insert the point of the scissors into the slit made by the razor blade and cut the sclera with a shallow snipping motion. Turn the eye as you continue the cutting action. Cut the sclera all the way around the ball of the eye. You will need to support the eye with your forceps while you complete this step of the dissection. Do not be surprised if some fluid from the eye oozes from the slit as you make this cut.



**Step 5:** Arrange the two hemispheres of the eye as you see in the middle picture. Observe the semi-fluid that fills the central cavity of the eye. It is transparent in the living eye but might be cloudy in the preserved specimen. The vitreous humor along with the aqueous humor (found behind the cornea) helps to maintain the shape of the eye. The retina lines the posterior (back) side of the eye and extends forward to the ciliary body (beneath the iris, used to make aqueous humor). Use your probe to lift and pull the retina back from the underlying choroid layer (found in-between the sclera and the retina, used to nourish the back of the eye). See the photograph on the right side above. Notice that the retina is only firmly attached to the choroid at one place. This region is the optic disc or blind spot. Here the nerve fibers leave the retina and form the optic nerve which is directly behind the blind spot.

**Step 6:** Use your forceps to peel the retina away from the underlying choroid coat. The retina should remain attached at the blind spot. The choroid coat is dark and relatively thin. Use your forceps or probe to gently separate the choroid from the outer sclera. Verify that the eye has three distinct layers, the retina, choroid and sclera. See left photograph above. The choroid contains an extensive network of blood vessels that bring nourishment and oxygen to itself and the other two layers. The dark color, caused by pigments, absorbs light so that it is not reflected around inside of the eye. The tapetum lucidum, which is not found in the human eye, functions to reflect light onto the retina. It especially helps animals with night vision since it can reflect light even at very low intensities. It is shiny, glittering with a bluish color.

**Step 7:** Use your forceps and probe to remove the vitreous humor from the anterior (front) hemisphere of the eye. See right photograph above. This will take some time and effort as the semi-fluid material separates easily. It helps to turn the hemisphere on edge and to use a scrapping motion to remove the fluid. Try not to disturb the lens that is just below the vitreous humor.



**Step 8:** Removal of the vitreous humor reveals the lens, ciliary body and suspensory ligaments. In the normal condition the lens is transparent except, when as a condition of aging, the lens turns cloudy. The cloudy condition, called cataract, prevents or reduces the amount of light reaching the retina. Cataract can be treated by removing the lens and replacing it with a stiff artificial one. The normal lens is convex shaped and somewhat elastic. It is held in place by the suspensory ligaments that in turn join with the smooth muscle containing ciliary body. When the smooth muscle fibers contract the resulting force flattens the lens and the degree of bending of the light rays is reduced. Relaxation of the smooth muscle results in a thickening of the lens and a greater bending of the rays of light.

**Step 9:** Remove the lens by pulling it free from its attachments. Note the shape of the lens, its stiffness and opaqueness. Suspensory ligaments may also be visible along the edge of the lens.

**Step 10:** When the lens is removed, an opening, allowing light to enter the eye is seen. This opening, the pupil is located in the center of the iris. Two muscle layers of the iris regulate the size of the pupil. One layer increases the pupil size with decreasing light intensity and the other layer reduces pupil size with increasing light intensity. Note the oblong shape of the sheep pupil, in humans the pupil is circular. The back side of the iris can be seen just above the pointer in the photograph. Part of the iris is being lifted by the pointer but the iris continues all the way around the pupil opening. A second cavity or space is present between the iris and the cornea. This space is filled with a second semi-liquid fluid, the aqueous humor. This fluid, like the vitreous humor helps to maintain the shape of the eye. Glaucoma is a condition where the fluid pressure becomes too high causing eye damage.

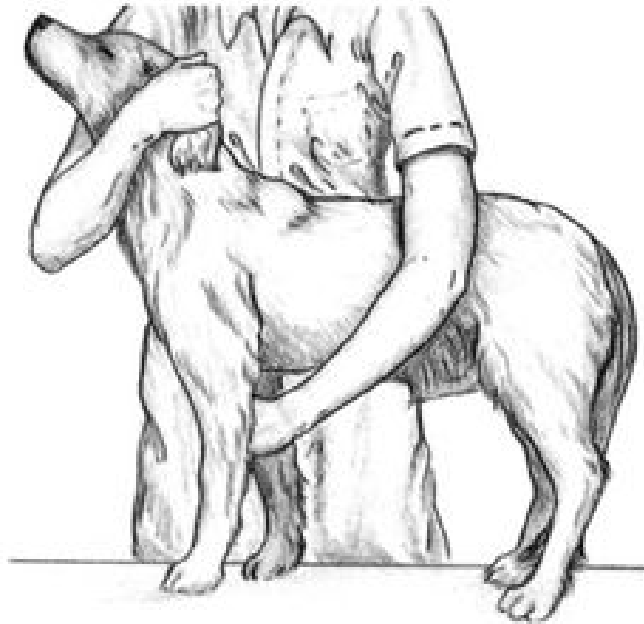**Step 11:** Remove the cornea from the front eye hemisphere. Use a scalpel to puncture a small slit at the boundary between the cornea and sclera. Then insert the scissors into the slip and cut all the way around the cornea to remove it. Notice the thickness of the cornea. How does it compare to the thickness of the sclera? Carefully observe the front side of the iris and pupil. Which structure of the eye would be just behind the pupil opening?



**Step 12:** Place all of your eye structures in the red biohazard bag. Wipe your dissection tray with an antibacterial cloth and put dissecting tools in the disinfectant jar. Clean your lab area with another antibacterial cloth. Remove gloves and wash your hands.



# Small Animal Restraint

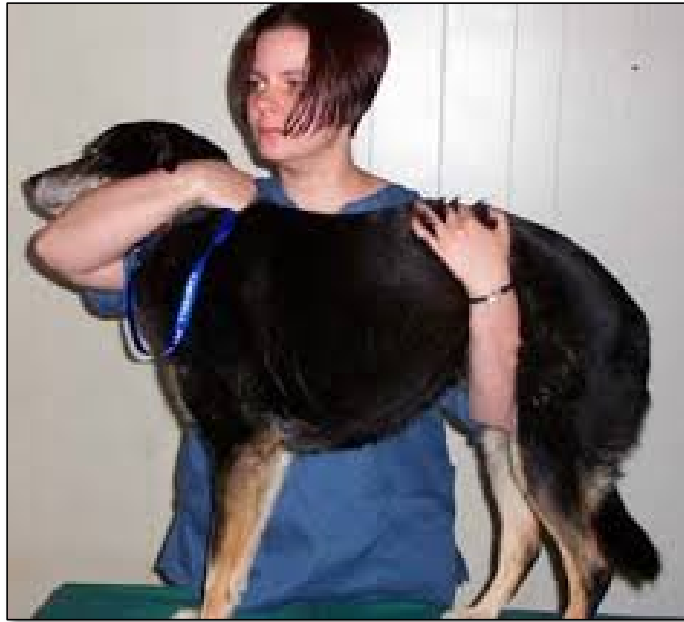

# Sitting Restraint



1. Move one arm under jaw and hug head to body
2. Move other arm in front of hip and grasp under belly
3. Used for examinations and injections

# Standing Restraint



1. Move one arm under jaw and hug head to body
2. Move other arm in front of hip and grasp under belly
3. Used for examinations and injections

# Restraint for Jugular Vein Access



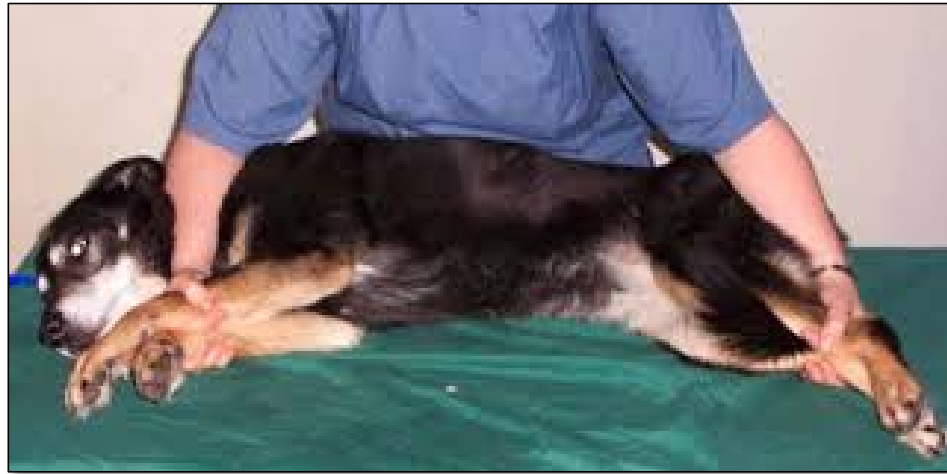1. One arm under the jaw and hugging head to body
2. A muzzle is recommended for this hold
3. Leg behind back to prevent dog from backing up
4. Other arm stabilizing body by grasping limb or holding arm across the dog's chest
5. Used for large volume blood draw

# Restraint for Cephalic Vein Access



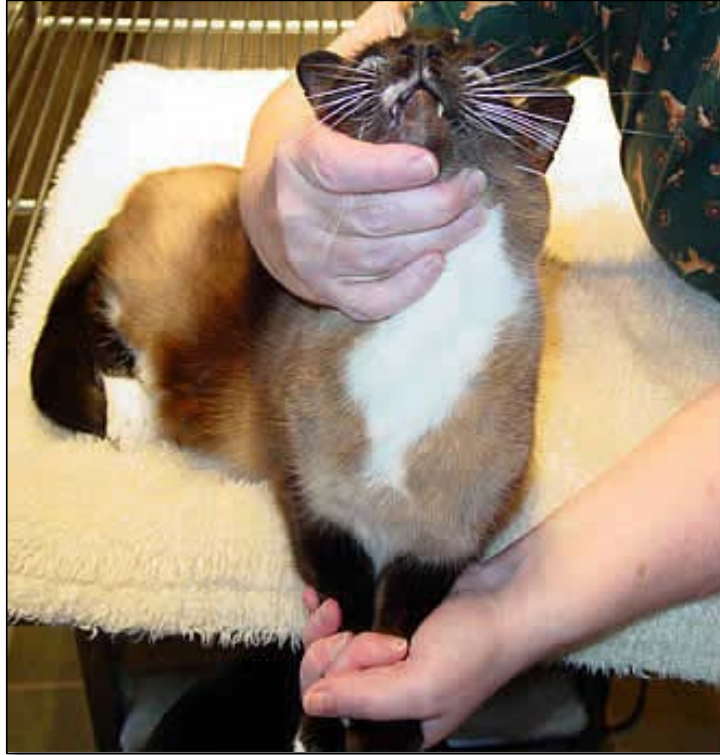1. One arm under the jaw and hugging head to body
2. Other arm pressed against flank and grasping elbow
3. Thumb grasps the medial skin and twists laterally to expose vein
4. Used mostly for IV catheter placement or small volume blood draw

# Restraint for Saphenous Vein Access



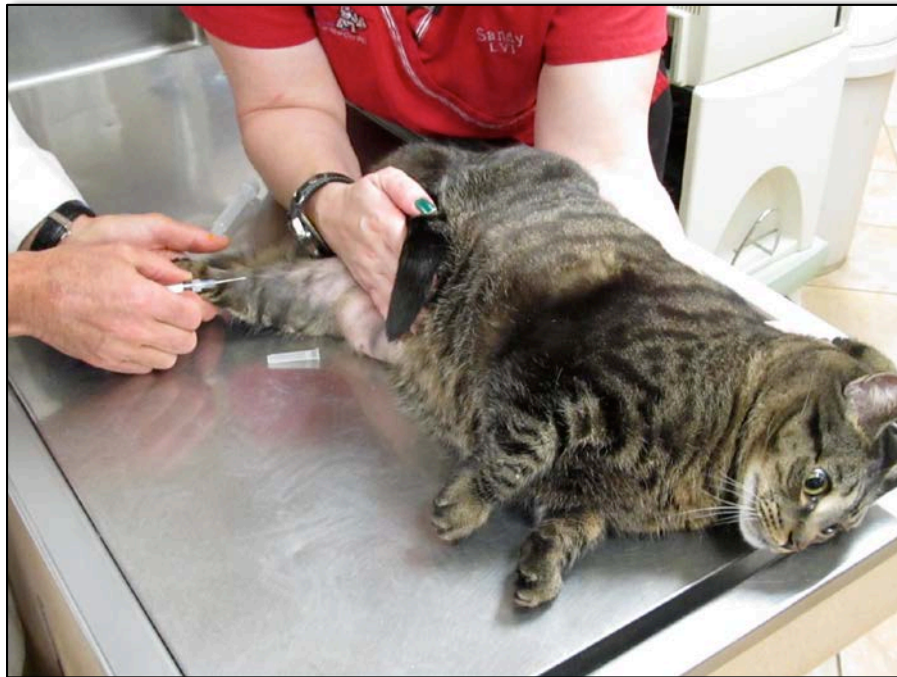1. One arm goes over neck and grasps the bottom leg
2. Other arm goes over hip and grasps the bottom leg
3. If small dog or skinny legs, grasp both legs
4. Used mainly for bandage changes or small blood volume draws from lateral saphenous vein

# Restraint for Cat Jugular Vein Access



1. One hand under jaw
2. A muzzle is recommended for this hold
3. Other hand holds both front legs and stretches
4. Used for large volume blood draw

# Restraint for Cat Medial Saphenous Access

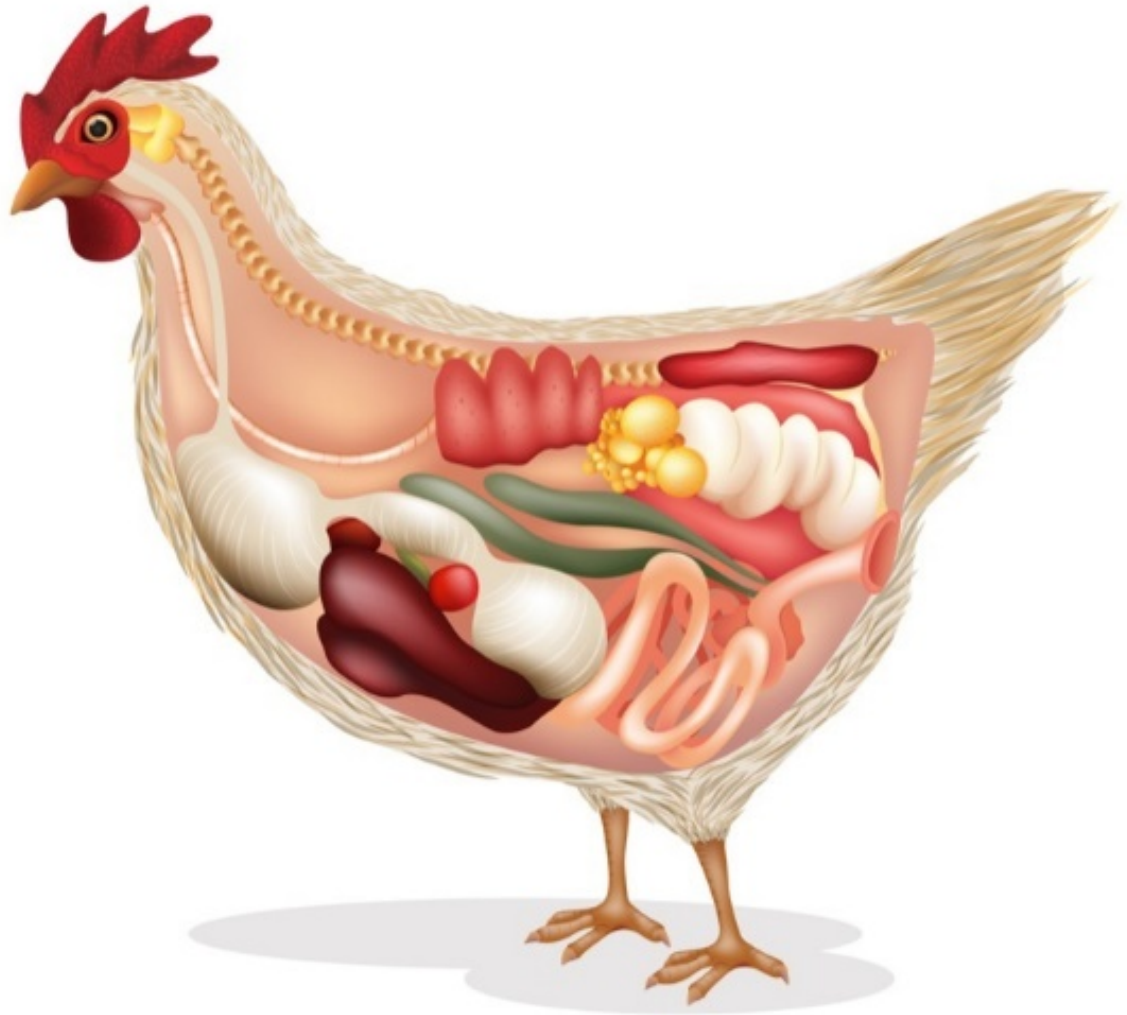


1. Use one hand to hold scruff of neck
2. Use other hand to hold top foot and press on lower thigh (like a karate chop)
3. Stretch to keep front claws from reaching back leg
4. Used for any volume blood draw



# Chicken Necropsy





---

University of Arkansas, United States Department of Agriculture and County Governments Cooperating

The Arkansas Cooperative Extension Service offers its programs to all eligible persons regardless of race, color, sex, gender identity, sexual orientation, national origin, religion, age, disability, marital or veteran status, genetic information, or any other legally protected status, and is an Affirmative Action/Equal Opportunity Employer.